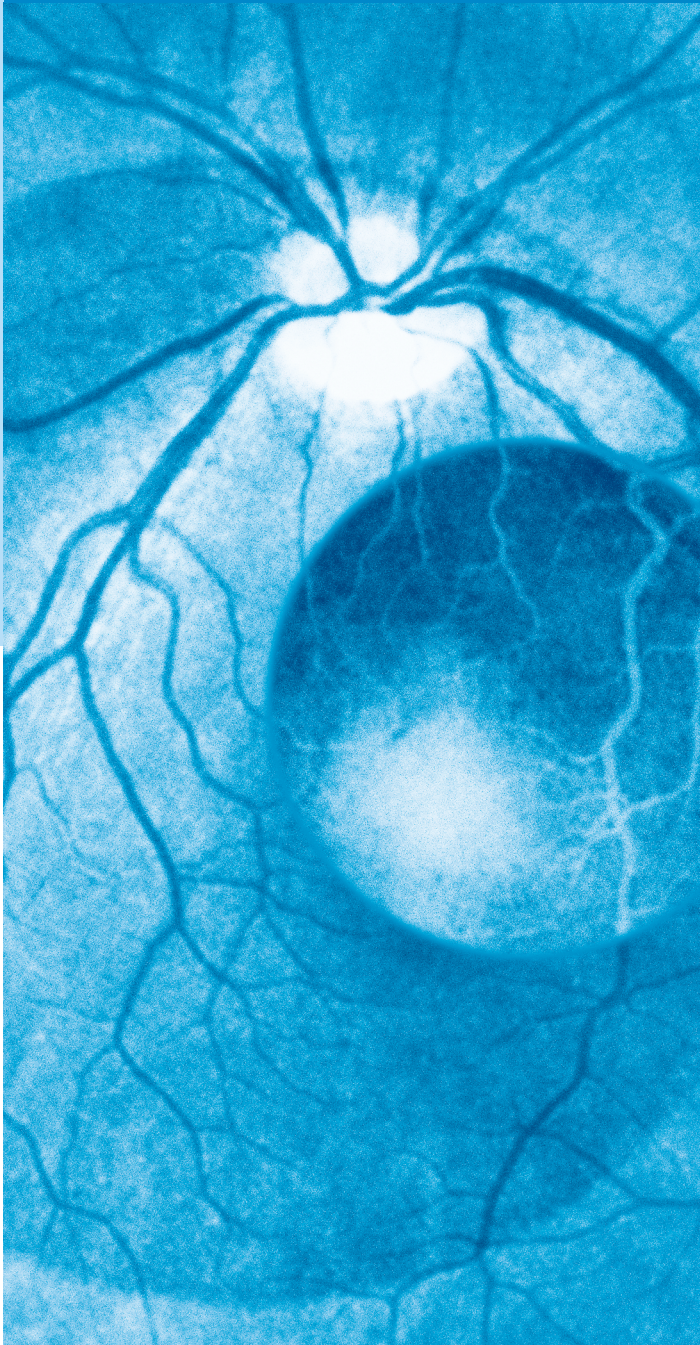


Klinische Monatsblätter für Augenheilkunde

November 2006 • Page S1–S48 • Volume 223

www.thieme-connect.de S4 • 2006

Volume 223 November 2006 Page S1–S48



Supplement

► Principles and Guidelines of a Curriculum for Education of the Ophthalmic Specialist

Presented by International Task Force
on Resident and Specialist Education
in Ophthalmology

On Behalf of The International Council
of Ophthalmology (ICO)

Chairmen of Task Force:
Morton F. Goldberg, MD (USA)
Andrew G. Lee, MD (USA)

Editor and Education Director:
Mark O. M. Tso, MD (USA) (China)

Klinische Monatsblätter für Augenheilkunde

November 2006 · Page S1 – S48 · Volume 223 · Supplement 4

11 · 2006

S4	I. Preamble
S8	II. Optics
S10	III. Retinoscopy and Refraction
S10	IV. Cataract and Lens
S12	V. Contact Lens
S13	VI. Cornea, External Diseases, and Refractive Surgery
S16	VII. Glaucoma
S18	VIII. Neuro-Ophthalmology
S19	IX. Ophthalmic Histopathology
S20	X. Oculoplastic Surgery and Orbit
S22	XI. Pediatric Ophthalmology and Strabismus
S25	XII. Vitreoretinal Diseases
S27	XIII. Uveitis
S28	XIV. Ocular Oncology
S29	XV. Low Vision Rehabilitation
S29	XVI. Ophthalmic Practice and Ethics
S30	XVII. General References

S31	XVIII. Literature and Studies for Review
	General References (Books)
	Herpetic Eye Disease Study (HEDS) I
	Fluorouracil Filtering Surgery Study (FFSS)
	Normal Tension Glaucoma Study
	Ocular Hypertension Treatment Study (OHTS)
	Glaucoma Laser Trial (GLT) and Glaucoma Laser Trial Follow-up Study (GLTFS)
	Optic Neuritis Treatment Trial (ONTT)
	Ischemic Optic Neuropathy Decompression Trial (IONDT)
	Studies of the Ocular Complications of AIDS (SOCA)
	Branch Vein Occlusion Studies (BVOS)
	Macular Photocoagulation Study (MPS)
	Age-Related Eye Disease Study (AREDS)
	Verteporfin in Photodynamic Therapy (VIP)
	Treatment of Age-Related Macular Degeneration with Photodynamic Therapy (TAP)
	Silicone Study
	Submacular Surgery Trials (SST)
	Multicenter Trial of Cryotherapy for Retinopathy of Prematurity (CRYO-ROP)
	Central Vein Occlusion Study (CVOS)
	Diabetes Control and Complications Trial (DCCT)
	Diabetic Retinopathy Study (DRS)
	Early Treatment Diabetic Retinopathy Study (ETDRS)
	Randomized Trial of Acetazolamide for Uveitis-Associated Cystoid Macular Edema
	Collaborative Ocular Melanoma Study (COMS)
	Additional Suggested Literature: Review Articles

Klinische Monatsblätter für Augenheilkunde

November 2006 · Page S1 – S48 · Volume 223 · Supplement 4

11 · 2006

Preface

In 1999 and 2000, the International Council of Ophthalmology and the Academia Ophthalmologica Internationalis developed an International Ophthalmology Strategic Plan to preserve and restore vision – Vision for the Future.

This strategic plan involved a multi pronged approach to reduce visual impairment and blindness worldwide, and the following actions have been completed or are underway to make this plan a reality:

- ▶ IFOS/ICO fellowships have been established under the leadership of Professor Balder Gloor to provide overseas educational opportunities for junior ophthalmic faculty in ophthalmology departments in developing countries.
- ▶ The International Assessment for Ophthalmologists in both clinical and basic sciences has been successfully implemented by Professor Peter Watson.
- ▶ Eye care guidelines to develop evidence-based eye care delivery, are being developed under the leadership of Professor Richard Abbott.
- ▶ Advocacy for preservation and restoration of vision to increase public awareness of blindness prevention is being headed by Professor Hugh Taylor.
- ▶ Research in ophthalmology and vision, for development of new and improved therapies for blinding diseases, is being led by Professor Alfred Sommer.

The ICO Strategic Planning Group also decided that ophthalmic education is the cornerstone to improve eye care globally. As part of this Strategic Plan, four International Task Forces were established to develop curricula for training of the ophthalmic specialist, para-ophthalmic personnel, medical students, and for continuing medical education.

After years of hard work by multiple international panels, the four curricula are being presented for publication in this issue of *Klinischen Monatsblätter für Augenheilkunde* as supplements.

The curricula are presented, not as mandatory standards of training or practice, but as an educational tool and consensus example to stimulate multi-levels of training including basic, standard, and advanced programs. The International Council of Ophthalmology realizes the wide variability of educational standards, patterns and prevalence of diseases, and social structures for provision of eye care in geographic regions, and therefore encourages continuous modification of these curricula according to the needs of different global communities.

Traditionally, ophthalmology residency training runs on an "Apprenticeship System" where the teaching contents and format for trainees frequently depend on the whims of the trainers. In recent decades, there is a general movement to shift the apprenticeship system of education to a curriculum-based system of

education in which goals, expectation, knowledge base, competencies and technical training are carefully defined. The four international curricula are prepared with this general direction in mind.

The panels, which drafted these curricula, understand the importance of accessibility of the educational materials and availability of mentorship. The International Task Forces encourage the donation of good teaching material to be included in these curricula and to be available for teachers and students worldwide. The ICO also proposes the twinning of training programs of industrialized and developing countries to encourage the exchange of mentors. It is recognized that competency in the practice of medicine depends on factors other than medical knowledge as outlined in these curricula. Inter-personal communication skills, professionalism, system-based factors, surgical skills, a solid ethical foundation, and others contribute substantially to the expertise and competence of eye care specialists. These curricula only provide a framework to initiate the training process.

Efficiency of eye care in the modern practice of ophthalmology depends on teamwork, consisting of ophthalmic physician specialists, ophthalmic nurses, orthoptists, optometrists, clinic managers, and others. The balance and composition of an eye care team is critical for maximum productivity of the care provided. So in these curricula, training of the eye care team is being covered.

The rapid development of medical technology in the 21st Century has resulted in greater discrepancies in the levels of medical care in various geographic locations of the world. However, the world does not work unless the world works together. These international curricula of ophthalmic education are attempts to encourage different players in the international ophthalmic educational arena to work together to develop a forward movement for improved eye care worldwide.

The International Council of Ophthalmology and the International Task Forces on Ophthalmic Education would like to thank the editors, Professors Gerhard K. Lang and Gabriele E. Lang, Project Manager, Katrin Stauffer of *Klinischen Monatsblätter für Augenheilkunde*, for their gracious assistance in publishing these curricula.

Mark O.M. Tso, MD, D. Sc.

Editor of International Curricula on Ophthalmic Education
Education Director

International Council of Ophthalmology
G.O.H. Naumann, MD

Former President (1998 – 2006)

International Council of Ophthalmology
Bruce E. Spivey, MD

President

International Council of Ophthalmology

Principles and Guidelines of a Curriculum for Education of the Ophthalmic Specialist

Presented by International Task Force on Resident and Specialist Education in Ophthalmology – On Behalf of The International Council of Ophthalmology (ICO)

Chairmen of Task Force

Morton F. Goldberg, MD (USA)
Andrew G. Lee, MD (USA)

Editor and Education Director, ICO

Mark O.M. Tso, MD (USA) (China)

Bibliography

DOI 10.1055/s-2006-951843
Klin Monatsbl Augenheilkd
2006; 223, Suppl 4: S3–S48
© Georg Thieme Verlag KG
Stuttgart · New York ·
ISSN 1431-634X

Corresponding Author

Mark O.M. Tso, MD
Wilmer Eye Institute, Johns
Hopkins University, 457 Woods
Building, 600 North Wolfe
Street, Baltimore, MD 21287-
9142, USA; and Peking Uni-
versity Eye Center, The Third
Teaching Hospital, Peking Uni-
versity, 49 North Garden Road,
Haidian District, Beijing
100083, People's Republic of
China, Fax: 410-614-1114
(USA); Fax: 8610-8208-9951
(China)

Major Contributors:

Morton F. Goldberg, MD (USA)
Andrew G. Lee, MD (USA)
And Other Members of International Task Force*

Executive Committee of ICO [1998–2006]:

Gottfried O.H. Naumann, MD, President
(Germany)
Mark O.M. Tso, MD, Vice-President (USA) (China)
Bruce E. Spivey, MD, Secretary General (USA)
Balder Gloor, MD, Treasurer (Switzerland)

Key to Training Levels

The Task Force recognizes the variability in training duration and nomenclature in the various countries. We recommend that readers of the ICO curriculum adapt the levels of training to their individual needs and local training requirements. In the United States, Post-Graduate Year 1 (after completion of medical school) is one-year of general training (i.e., internship, preliminary medicine, surgery, transitional year, etc.).

Basic Level: Corresponding to United States Post-Graduate Year 2 (PGY-2)

Standard Level: Corresponding to United States Post-Graduate Year 3 (PGY-3)

Advanced Level: Corresponding to United States Post-Graduate Year 4 (PGY-4)

Acknowledgement: *Past and present members of the International Task Force on Resident and Specialist Education in Ophthalmology as well as other contributors to this work: Morton F. Goldberg, MD, Chair (USA); Andrew Lee, MD (USA); Ehud Assia, MD (Israel); Rafael I. Barraquer, MD (Spain); Britt Beding-Barnekow, MD (Sweden); Francis A. Billson, MD (Australia); Francisco Contreras, MD (Peru); Jose G. Cunha-Vaz, MD (Portugal); M. Daud Khan, MD (Pakistan); Philip Lam, MD (Hong Kong); Akef El Maghraby, MD (Saudi Arabia); Con Moshegov, MD (Australia); Denis O'Day, MD (USA); Gullapalli N. Rao, MD (India); Ronald Smith, MD (USA); Professor Masanobu Uya-

ma, MD (Japan); Peter Watson, FRCS, FRCOphth (United Kingdom); Peter Wiedemann, MD (Germany); Georges Yaya, MD (Central African Republic); and Zbigniew Zagorski, MD (Poland). ICO gratefully acknowledges the editorial efforts of Jenni Anderson and Lenalee Fulton in coordinating and assembling these curricula.

Publication of this curriculum was partially supported by a contribution from the International Council of Ophthalmology Foundation

Manuscript Editor: Tina-Marie Gauthier

I. Preamble



An ophthalmologist is a doctor of medicine (MD or equivalent degree) who specializes in the eye and visual system. As a licensed medical doctor, the ophthalmologist's ethical and legal responsibilities include the care of individuals and populations suffering from diseases of the eye and visual system. Such care requires not only core competencies for an ophthalmic physician, but also a set of specialized cognitive capabilities and an array of technical skills. Specialist training is designed to provide a structured program of learning that facilitates the acquisition of knowledge, understanding, skills, and attitudes to a level appropriate for an ophthalmic specialist who has been fully prepared to begin their career as an independent consultant in ophthalmology.

Goals

The curriculum provides an outline of essential intellectual and clinical information (cognitive and technical skills) that is necessary for a modern, comprehensive ophthalmologist. The ICO curriculum is designed to provide a content outline for training. The precise details of the curricular learning plan should be modified by the readers of this curriculum to meet their local needs and available resources. These modifications should include: 1) when the learning will occur (i.e., duration, length, frequency, and timing of training), 2) where the learning will take place (i.e., location of learning, which rotations), 3) who will participate (i.e., who will teach, who will learn, who will assess learning and teaching), and 4) how will the teaching and learning be measured (i.e., teaching and assessment methods).

Core competencies and technical skills are described briefly in this preamble. Though not specifically addressed here, skills in epidemiology and research methodologies are important for the well-rounded ophthalmologist.

Blindness and reduced vision affect hundreds of millions of people throughout the world, and the causes vary widely. The knowledge required to understand and treat the diseases commonly encountered in one part of the world may be entirely different from that required in other locations; for example, trachoma vs. age-related macular degeneration, or nutritional blindness vs. diabetic retinopathy, etc. Accordingly, the curricular components deemed essential in one geographical locale or one cultural system may be relatively unimportant in other regions, depending upon prevalence of diseases, the medical infrastructure, and other factors.

Levels of economic and social development also vary widely throughout the world. Treatments and techniques considered indispensable for one group of people might be unattainable or unimportant for others, due to lack of economic resources, unavailability of highly specialized personnel or equipment, and many other factors. Thus, the standards proposed herein should be considered as aspirational guidelines to be sought and attained as soon as practicable. They cannot be instantly achieved in all parts of the world, desirable as they might be. Standards may need to be modified according to local priorities, goals, needs, culture, governmental policies, social systems, financial constraints, varying use of para-ophthalmic personnel, and differing tangible resources. Even in highly developed societies, with large and well-financed governmental systems of health care delivery, this document should be considered a "work in progress" and be revised and modified to suit local needs as

well as respond to expanding knowledge and technology. In this regard, feedback to the ICO, with specific suggestions for changes and improvement in these guidelines, is earnestly solicited from the readers and will be greatly appreciated by the authors of this document and by the leadership of the ICO.

History of Task Force on Resident and Specialist Education in Ophthalmology

The ICO has had an intense interest and commitment to ophthalmic education for many years. Under the leadership of Professor Maurice H. Luntz, for example, the International Committee for Teaching and Continuing Educational Systems of the International Council of Ophthalmology has described training programs throughout the world and has offered guidelines for education of ophthalmologists on numerous occasions during the 1980s and 1990s, including presentations at the 14th, 24th, and 26th quadrennial meetings of the ICO.

In 2001, the ICO and the Academia Ophthalmologica Internationalis (AOI) published, "Vision for the Future," an international strategic plan to preserve and restore vision. Within this plan, a task force on resident and specialist training in ophthalmology, under the direction of Professor Ronald E. Smith, noted the following:

- ▶ Guidelines for ophthalmology training are not fixed and should not be viewed as rigid or mandatory.
- ▶ Training should be provided through a combination of lectures, supervised patient care, and graduated, hands-on procedural and surgical experience, research, and independent study.
- ▶ The focus should be on acquisition of knowledge and skills related to ophthalmology, and development of an appreciation for the importance of vision research, life-long learning, and the education of the public and other physicians.
- ▶ The curriculum should be approximately 3 – 5 years in length, depending upon the individual country or region, and should prepare the graduating ophthalmologist for an examination or testing process that leads to licensure, registration, or a related certification system.
- ▶ Facilities should include: up-to-date ophthalmic equipment and instruments, examining rooms dedicated to ophthalmic education, links to hospitals or other facilities for anesthesia, radiology, clinical testing laboratories, other diagnostic services, and modern surgical suites with appropriate equipment. In addition, repositories of library materials or Internet access to ophthalmic educational materials, such as journals, texts, tests, videotapes, and related resources, should be available, along with facilities for lectures and conferences (including audiovisual equipment).
- ▶ A culture of learning and teaching should be established that includes modern facilities, and a committed and dedicated cadre of skilled educators.
- ▶ Periodic audits and assessments of progress of individual trainees should include formal tests (oral or written). Examinations developed by Professor Peter Watson and a committee of specialists can be accessed by email at ICO.exam@btinternet.com; these examinations require extensive knowledge in both basic and clinical sciences. Review of case logbooks (surgical and non-surgical) should regularly occur at each stage of the training process. The logbook should be used for all laser and surgical procedures and might include preoperative indications, intraoperative complications, and

postoperative complications. The logbook is an important educational, clinical, and administrative tool.

- In addition, it is now considered desirable for supervised surgical training to begin as soon as possible after entry into the ophthalmic educational system. Graduated levels of responsibility should occur, commensurate with a trainee's education and set of skills. Various educational adjuncts should be available, including practice surgery on animal or outdated eye bank eyes, dissections of cadavers, videotapes, and web-based systems of instruction. Videotaping surgery performed by trainees is extremely useful, both for the surgeon in training and for the mentor. Assisting senior surgeons on a regular basis is a time-honored and helpful educational activity for the trainee. In addition to acquiring intraoperative skills, the ophthalmologist in training must acquire abilities for preoperative selection of suitable surgical candidates and in postoperative care. Details of surgical training (i.e., minimum requirements) are not included here, because local customs and legal requirements differ throughout the world. In some countries, limited standardized training programs are offered for surgical technicians who have been perceived as not fully trained ophthalmologists, but who are necessary for the care of populations having no access to such ophthalmologists. Guidelines for logbook requirements and minimum numbers of supervised surgical cases vary from country to country. Valuable information on these issues can be obtained from: www.rcophth.ac.uk, www.acgme.org, www.ranzco.edu, and www.aao.org.
- Periodic audits of individual training programs are also suggested.

The ICO Task Force on Resident and Specialist Training

In order to prepare a document having value for widely different nationalities, cultures, medical status, and socioeconomic developments, ophthalmic curricula were initially solicited and evaluated from national and local agencies throughout the world. Representative documents were received and analyzed from over 30 countries. Based upon these and related materials, the ICO Task Force on Ophthalmology for Resident and Specialist Training prepared the curricular guidelines and standards for international use. In draft form, this document was initially reviewed by over 100 representatives of the ICO, the AOI, other transnational and national eye organizations, the American Academy of Ophthalmology, the Association of University Professors of Ophthalmology in the United States, and numerous university departments of ophthalmology throughout the world. In addition, advice was received from ophthalmic leaders with different subspecialty skills and expertise in Africa, Asia, Australia, New Zealand, Europe, North America, Central America, South America, and the United Kingdom. This review process took over 18 months to complete. In addition, the draft document was placed on the website of the ICO for over six months in order to elicit feedback and suggestions before promulgating it in its present (and modifiable) form. The draft was also presented in person to the Asia-Pacific Ophthalmology meeting in Bangkok, Thailand, 2003, and to the American University Professors of Ophthalmology meeting in Sarasota, Florida, 2003.

Format of the ICO Curriculum for Education of the Ophthalmic Specialist

The ICO curriculum presented here is an outline for three years of supervised ophthalmic training at progressively more advanced levels. Following medical school graduation plus one year of post-graduate (non-ophthalmic) medical training, the Basic Level of education corresponds to United States post-graduate year 2 (PGY2). The Standard Level corresponds to United States post-graduate year 3 (PGY3); and the Advanced Level corresponds to United States post-graduate year 4 (PGY4). We only provide the corresponding levels of training for the United States for clarification purposes and not as a recommendation for duration or length of training which are subject to local custom and regulation. As noted previously, local, national, or transnational cultural systems will require modification of this duration (and content) of training. Indeed, in some locations, where clinical needs are urgent and pressing, marked abbreviations of the training program will be necessary in order to provide the region with sufficient numbers of practitioners, both medical and surgical (although at reduced levels of competence in certain areas of knowledge). For each level within the curriculum presented here, both cognitive skills and technical skills are listed. There is some planned repetition within the standard and advanced levels, because some areas are complex or important enough to deserve this emphasis. The following categories of knowledge are included: optics; retinoscopy and refraction; cataract and lens; contact lens; cornea, external diseases and refractive surgery; glaucoma; neuro-ophthalmology; ophthalmic histopathology; oculoplastic surgery and orbit; pediatric ophthalmology and strabismus; vitreoretinal diseases; uveitis; ocular oncology; low vision rehabilitation; and ophthalmic practice and ethics.

In some countries, ophthalmic training extends beyond the three-year curriculum offered here, so that exceptional mastery of select subspecialty areas (for example, cornea, retina, glaucoma, etc.) can be achieved. Graduates of such programs are designated by different titles (e.g., "fellows" in North America). It is not the goal of the attached curricular outline to encompass all the knowledge and skills of such subspecialty areas, but mastery of the advanced level of this curriculum will provide introductory and transitional knowledge and skills leading towards even higher levels of sophistication. Individuals at these subspecialty levels of training ordinarily should also have accomplished the goals of the attached three-year curricular outline that is offered here.

A list of references is provided for the curriculum, but new information, which accrues regularly and rapidly, will need to be added to this list by the reader. Evidence-based medicine, in which therapeutic decisions are based on documented, verifiable and validated information, is appropriately assuming increasing importance as an educational framework upon which individual physicians should make recommendations for their patients. Whenever possible, those references and sources of knowledge providing such information should receive precedence and preference by both teachers and students of clinical ophthalmology. Links to the practice of evidence-based medicine can be found at www.aao.org.

Core Competencies and Subcompetencies

In addition to the specialized cognitive and technical skills described in this curriculum, several generic core "competencies" are expected of ophthalmic, as well as other, medical specialists,

as promulgated by the United States Accreditation Council for Graduate Medical Education (ACGME). Again, there are world-wide differences in nomenclature for the general competencies and we provide the United States version of these general competencies for all physicians for clarification purposes only. Local customs, practices, resources, and regulatory environments will dictate the application of these competencies for individual programs. The ACGME website is www.acgme.org.

These core competencies include:

- ▶ Patient care.
- ▶ Medical knowledge.
- ▶ Practice-based learning and improvement.
- ▶ Interpersonal and communication skills.
- ▶ Professionalism.
- ▶ Systems-based practice.

Patient Care

- ▶ Trainees ("residents") must be able to provide patient care that is compassionate, appropriate, and effective for the treatment of health problems and the promotion of health. Residents are expected to:
 - ▶ communicate effectively and demonstrate caring and respectful behaviors when interacting with patients and their families;
 - ▶ gather essential and accurate information about their patients;
 - ▶ make informed decisions about diagnostic and therapeutic interventions, based on patient information and preferences, up-to-date scientific evidence, and clinical judgment;
 - ▶ develop and carry out patient management plans;
 - ▶ counsel and educate patients and their families;
 - ▶ use information technology to support patient care decisions and patient education; perform competently the medical and invasive procedures considered essential for the area of practice;
 - ▶ provide health care services aimed at preventing health problems or maintaining health;
 - ▶ work with health care professionals, including those from other disciplines, to provide patient-focused care.

Medical Knowledge

Residents must demonstrate knowledge about established and evolving biomedical, clinical, and cognate (e.g., epidemiological and social-behavioral) sciences and the application of this knowledge to patient care. Residents are expected to:

- ▶ demonstrate an investigatory and analytic thinking approach to clinical situations;
- ▶ know and apply the basic and clinically supportive sciences which are appropriate to ophthalmology.

Practice-based Learning and Improvement

Residents must be able to investigate and evaluate their patient care practices, appraise and assimilate scientific evidence, and improve their patient care practices. Residents are expected to:

- ▶ analyze practice experience and perform practice-based improvement activities using a systematic methodology;
- ▶ locate, appraise, and assimilate evidence from scientific studies related to their patients' health problems;
- ▶ obtain and use information about their own population of patients and the larger population from which their patients are drawn;
- ▶ apply knowledge of study designs and statistical methods to the appraisal of clinical studies and other information on diagnostic and therapeutic effectiveness;

- ▶ use information technology to manage information, access on-line medical information; and support their own education; and facilitate the learning of students and other health care professionals.

Interpersonal and Communication Skills

Residents must be able to demonstrate interpersonal and communication skills that result in effective information exchange and teaming with patients, patients' families, and professional associates. Residents are expected to:

- ▶ create and sustain a therapeutic and ethically sound relationship with patients;
- ▶ use effective listening skills and elicit and provide information using effective nonverbal, explanatory, questioning, and writing skills; and
- ▶ work effectively with others as a member or leader of a health care team or other professional group.

Professionalism

Residents must demonstrate a commitment to carrying out professional responsibilities, adherence to ethical principles, and sensitivity to a diverse patient population. Residents are expected to:

- ▶ demonstrate respect, compassion, and integrity; a responsiveness to the needs of patients and society that supercedes self-interest; accountability to patients, society, and the profession; and a commitment to excellence and on-going professional development;
- ▶ demonstrate a commitment to ethical principles pertaining to provision or withholding of clinical care, confidentiality of patient information, informed consent, and business practices; and
- ▶ demonstrate sensitivity and responsiveness to patients' culture, age, gender, and disabilities.

Systems-based Practice

Residents must demonstrate an awareness of and responsiveness to the larger context and system of health care and the ability to effectively call on system resources to provide care that is of optimal value. Residents are expected to:

- ▶ understand how their patient care and other professional practices affect other health care professionals, the health care organization and the larger society, and how these elements of the system affect their own practice;
- ▶ know how types of medical practice and delivery systems differ from one another, including methods of controlling health care costs and allocating resources;
- ▶ practice cost-effective health care and resource allocation that do not compromise quality of care;
- ▶ advocate for high quality patient care and assist patients in dealing with system complexities; and
- ▶ know how to partner with health care managers and health care providers to assess, coordinate, and improve health care and know how these activities can affect system performance.

Professional attitudes and conduct require that trainees must also have developed a style of care, which is:

- ▶ humane (reflecting compassion in providing bad news, if necessary; the management of the visually impaired; and recognition of the impact of visual impairment on the patient and society);
- ▶ reflective (including recognition of the limits of their knowledge, skills and understanding);
- ▶ ethical;

- integrative (including involvement in an inter-disciplinary team for the eye care of children, the handicapped, the systemically ill, and the elderly); and
- scientific (including critical appraisal of the scientific literature, evidence-based practice, and use of information technology and statistics).

Basic, Standard, and Advanced Levels of the Curriculum

The suggested curriculum in all chapters is designed to serve as a content outline for a fund of knowledge. The learning objectives are designed to emphasize recall of information understanding and application of basic sciences (e.g., anatomy, physiology, biochemistry, embryology, pharmacology), application of pathogenetic mechanisms to clinical problems, ordering and interpreting clinical, laboratory, imaging information, development of a differential diagnosis, implementation of a reasonable and appropriate therapeutic medical and/or surgical plan, and anticipation, recognition, and treatment of complications.

This curriculum is not designed to be all-inclusive, and individual programs should modify and apply the content as deemed appropriate to meet local, regional, and national priorities. It is intended solely as a guideline for the training of ophthalmic specialists. We recognize that certain specialized and expensive techniques of diagnosis and therapy are not universally available. All of the goals cannot invariably be achieved, but they should serve as aspirational guidelines towards achieving modern methods of diagnosis and care of common eye problems. It should be noted that parenthetical listings preceded by "e.g." represent examples only, and do not comprise a complete listing of items in the category.

Basic Level Goals: PGY-2

- A. Describe the basic principles of optics and refraction.
- B. List the indications for and prescribe the most common low vision aids.
- C. Perform the basic anterior segment (e.g., basic refraction, basic retinoscopy, slit lamp biomicroscopy) and posterior segment examination skills (e.g., dilated fundus examination, use of magnification and lenses, Hruby lens, 90 Diopter lens, three-mirror Goldmann contact lens) and to understand and use basic ophthalmic instruments (e.g., tonometer, lensometer).
- D. Triage and manage ocular emergencies (e.g., central retinal artery occlusion, giant cell arteritis, chemical burn, acute angle closure glaucoma, endophthalmitis, traumatically open globe).
- E. Perform minor external and adnexal surgical procedures (e.g., chalazion excision, corneal foreign body removal, use of foreign body corneal drill for removal of a rust ring, conjunctival biopsy, corneal scraping, isolated entropion).
- F. Identify the key examination techniques and management of basic and most common medical problems in the subspecialty areas of glaucoma (e.g., primary open angle glaucoma), cornea (e.g., dry eye, microbial keratitis), orbit and oculoplastics (e.g., common lid lesions, ptosis), retina (e.g., macular disorders, retinal detachment, diabetic retinopathy), and neuro-ophthalmology (e.g., optic neuropathy, ocular motor neuropathy, pupillary abnormalities, visual field defects).
- G. Describe indications for, performance of, and complications of common anterior segment surgery, (e.g., cataract extrac-

tion, trabeculectomy, peripheral iridectomy), and assist at surgery.

- H. Describe the common but serious genetic ocular disorders (e.g., retinal and macular dystrophies).
- I. Recognize the most common ophthalmic histopathology findings and recognize basic histopathology of common ocular lesions (e.g., retinal detachment, pterygium, corneal button removed at keratoplasty).

Standard Level Goals: PGY-3

- A. Describe the more advanced principles of optics and refraction.
- B. List the indications for and uses of more advanced low vision aids.
- C. Perform more advanced anterior segment (e.g., more complex refractions, including contact lens and postoperative refractions, intermediate retinoscopy, including moderate astigmatism, examination of young children, intermediate techniques of slit lamp biomicroscopy) and posterior segment examination skills (e.g., more advanced techniques of dilated fundus examination, including scleral depression, use of magnification and lenses to diagram and describe retinal lesions).
- D. Recognize and treat ocular emergencies (e.g., central retinal artery occlusion, giant cell arteritis, chemical burn, acute angle closure glaucoma, endophthalmitis, traumatically open globe), as well as the short and long-term complications of these disorders.
- E. Perform more advanced external and adnexal surgical procedures (e.g., isolated ectropion and isolated entropion repair, removal of small, localized, and benign lid lesions, pterygium excision).
- F. Identify the key examination techniques and management of the less common surgical problems in the subspecialty areas of glaucoma (e.g., secondary open angle and closed angle glaucoma), cornea (e.g., fungal and other less common microbial keratitis, corneal transplantation), ophthalmic plastic surgery (e.g., extensive benign and common lid lesions, ptosis), retina (e.g., primary retinal detachment, mild to moderate proliferative and non-proliferative diabetic retinopathy, and laser treatments), and neuro-ophthalmology (e.g., less common optic neuropathy, supranuclear palsies, myasthenia gravis, and more complex visual field defects).
- G. Perform common anterior segment surgery (e.g., cataract extraction, trabeculectomy, peripheral iridectomy).
- H. Recognize, and refer if indicated, some major genetic ocular disorders (e.g., neurofibromatosis I and II, tuberous sclerosis, von Hippel-Lindau disease, retinoblastoma, retinitis pigmentosa, macular dystrophy).
- I. Recognize more complex and difficult ophthalmic histopathology findings.

Advanced Level Goals: PGY-4

- A. Describe the advanced principles of optics and refraction (e.g., pre-refractive surgery and post-refractive surgery, higher order aberrations).
- B. List the indications for and uses of advanced low vision aids.
- C. Perform the most advanced anterior segment (e.g., complex refractions, advanced retinoscopy, advanced slit lamp biomicroscopy) and posterior segment examination skills (e.g.,

drawings of retinal detachments and scleral depressions, interpretation of macular disorders with slit lamp biomicroscopy).

- D. Manage or supervise the more junior trainees (e.g., medical students or medical residents) in the management of ocular emergencies (e.g., central retinal artery occlusion, giant cell arteritis, chemical burn, angle closure glaucoma, endophthalmitis).
- E. Perform more advanced external and adnexal surgical procedures (e.g., lacrimal gland procedures, complex lid laceration repair, (e.g., canalicular and lacrimal apparatus involvement).
- F. Identify the key examination techniques and management of complex but common medical and surgical problems in the subspecialty areas of glaucoma (e.g., complicated or postoperative primary and secondary open and closed angle glaucoma), cornea (e.g., unusual or rare types of microbial keratitis), ophthalmic plastic surgery (e.g., less common and more complex lid lesions, reoperation or complex or recurrent ptosis), retina (e.g., complex retinal detachment, tractional retinal detachments, and severe proliferative diabetic retinopathy, proliferative vitreoretinopathy), and neuroophthalmology (e.g., unusual optic neuropathy, neuroimaging, supranuclear palsies, uncommon visual field defects).
- G. Perform and treat complications of common anterior segment surgery, (e.g., cataract extraction, trabeculectomy, peripheral iridectomy).
- H. Recognize, evaluate, and treat, if possible, the major genetic ocular disorders (e.g., neurofibromatosis I and II, tuberous sclerosis, von Hippel-Lindau disease, retinoblastoma, retinitis pigmentosa, macular degenerations).
- I. Recognize uncommon or rare but classic ophthalmic histopathology findings.

Trainees at all levels of training should be able to describe the key features and apply in clinical practice the results of evidence-based medicine in ophthalmology, including, but not limited to, the results of the following clinical trials (see **XVIII. Literature and Studies for Review for full references**).

- ▶ Herpetic Eye Disease Study (HEDS) I
- ▶ Fluorouracil Filtering Surgery Study (FFSS)
- ▶ Normal Tension Glaucoma Study
- ▶ Ocular Hypertension Treatment Study (OHTS)
- ▶ Glaucoma Laser Trial (GLT) and Glaucoma Laser Trial Follow-up Study (GLTFS)
- ▶ Optic Neuritis Treatment Trial (ONTT)
- ▶ Ischemic Optic Neuropathy Decompression Trial (IONDT)
- ▶ Studies of the Ocular Complications of AIDS (SOCA)
- ▶ Branch Vein Occlusion Studies (BVOS)
- ▶ Macular Photocoagulation Study (MPS)
- ▶ Age-Related Eye Disease Study (AREDS)
- ▶ Verteporfin in Photodynamic Therapy (VIP)
- ▶ Treatment of Age-Related Macular Degeneration with Photodynamic Therapy (TAP)
- ▶ Silicone Study
- ▶ Submacular Surgery Trials (SST)
- ▶ Multicenter Trial of Cryotherapy for Retinopathy of Prematurity (CRYO-ROP)
- ▶ Central Vein Occlusion Study (CVOS)
- ▶ Diabetes Control and Complications Trial (DCCT)
- ▶ Diabetic Retinopathy Study (DRS)
- ▶ Early Treatment Diabetic Retinopathy Study (ETDRS)

- ▶ Randomized Trial of Acetazolamide for Uveitis-Associated Cystoid Macular Edema
- ▶ Collaborative Ocular Melanoma Study (COMS)

II. Optics



General Educational Objectives:

Understand the principles, concepts, instruments, and methods of optics outlined below and be able to apply them in clinical practice.

Basic Level Goals: PGY-2

A. Physical optics.

1. Properties of light.
 - a. Electromagnetic spectrum.
 - b. Wave theory.
 - c. Photon-particle theory.
2. Diffraction.
3. Interference and coherence.
4. Resolution.
5. Polarization.
6. Scattering.
7. Transmission and absorption.
8. Photometry.
9. Lasers.
10. Illumination.
11. Image quality.
12. Brightness and radiance.
13. Light propagation – optical media and refractive index.

B. Geometric optics.

1. Reflection (mirrors).
 - a. Laws of reflection.
 - b. Reflection at a plane surface (image and field of a plane mirror).
 - c. Reflection at curved surfaces (focal point and focal length of a spherical mirror).
 - d. Images and objects as light sources.
 - e. Refractive index.
 - f. Multiple lens system.
2. Refraction.
 - a. Laws of refraction (Snell's law).
 - i. passage of light from one medium to another.
 - ii. absolute index of refraction.
 - iii. total internal reflection.
 - b. Refraction at a plane surface.
 - c. Refraction at curved surfaces.
 - d. Critical angle and total internal reflection.
 - e. Image jump and displacement.
3. Prisms.
 - a. Definition.
 - b. Notation of prisms (e.g., prism diopters).
 - c. Uses in ophthalmology (diagnostic and therapeutic).
 - d. Types of prisms (plane, parallel, plate).
 - e. Prentice's rule.
 - f. Fresnel prism.
 - g. Refraction of light through a prism.
 - h. Thin prisms.
 - i. Prismatic effect of lenses.
4. Spherical lenses.
 - a. Cardinal points.

- b. Thin lens formula.
- c. Thick lens formula.
- d. Formation of the image.
- e. Vergence of light (diopter, convergence, divergence, vergence formula).
- f. Concave and convex.
- g. Magnification (linear, angular, relative size, electronic).
- h. Spherical decentration and prism power.
- i. Lens form.
- j. Binocular balancing.
- k. Refracting the basic low vision patient.
- 5. Astigmatic lenses.
 - a. Cylindrical lenses.
 - i. sphero-cylinder lenses and surfaces.
 - ii. cross cylinders (e.g., Jackson cross cylinder).
 - b. Maddox rod.
 - c. Toric lenses.
 - d. Conoid of Sturm.
- 6. Notation of lenses.
 - a. Spectacle prescribing.
 - b. Simple transposition.
 - c. Toric transposition.
- 7. Identification of unknown lenses.
 - a. Neutralization.
 - b. Focimeter.
 - c. Geneva lens measure.
- 8. Aberrations of lenses.
 - a. Correction of aberrations relevant to the eye (spherical, coma, astigmatism, distortion, pantoscopic tilt).
 - b. Duochrome test.
- 9. Lens materials.
- C. Clinical optics.
 - 1. Optics of the eye.
 - 2. Transmittance of light by the optic media.
 - 3. Schematic and reduced eye.
 - 4. Pupillary response and its effect on the resolution of the optical system (Stiles-Crawford effect).
 - 5. Visual acuity.
 - a. Distance and near acuity measurement.
 - b. Minimal (visible, perceptible, separable, legible).
 - c. Vernier acuity.
 - 6. Contrast sensitivity.
 - 7. Catoptric images.
 - 8. Emmetropia.
 - 9. Accommodation.
 - 10. Purkinje shift.
 - 11. Pinhole.
 - 12. Ametropia.
 - a. Myopia.
 - b. Hypermetropia (hyperopia).
 - c. Astigmatism.
 - d. Anisometropia.
 - e. Aniseikonia (Knapp's rule).
 - f. Aphakia.
 - g. Optical parameters affecting retinal image size.
 - 13. Accommodative problems.
 - a. Insufficiency.
 - b. Excess.
 - c. AC/A ratio.
 - 14. Refractive errors.
 - a. Prevalence.
 - b. Inheritance.
 - c. Changes with age.
 - d. Surgically induced.
- 15. Correction of ametropia.
 - a. Spectacle lenses.
 - b. Contact lenses.
 - c. Intraocular lenses.
 - d. Principles of refractive surgery.
- 16. Problems of spectacles in aphakia.
- 17. Effect of spectacles and contact lens correction on accommodation and convergence (amplitude, near point, far point).
- 18. Effective power of lenses.
- 19. Back vertex distance.
- 20. Spectacle magnification.
- 21. Calculation of intraocular lens power.
- 22. Presbyopia (measuring for near adds).
- 23. Low vision aids.
 - a. High reading addition.
 - b. Magnifying lenses.
 - c. Telescopic aids – Galilean telescope, Keplerian telescope.
- D. Clinical refraction.
 - 1. Retinoscopy.
 - 2. Subjective refraction.
 - 3. Measurement of back vertex distance (BVD).
 - 4. Muscle balance tests.
 - 5. Accommodative power.
 - 6. Measurement of interpupillary distance (IPD).
 - 7. Decentration of lenses and prismatic effect.
 - 8. Best form lens.
 - 9. Prescribing multifocal lenses.
 - 10. Prescribing for children.
 - 11. Cycloplegic refraction.
- E. Instruments and tests.
 - 1. Direct ophthalmoscope.
 - 2. Indirect ophthalmoscope.
 - 3. Retinoscope.
 - 4. Focimeter.
 - 5. Simple magnifying glass (loupe).
 - 6. Lensmeter.
 - 7. Glare and contrast testing.
 - 8. Potential acuity meter.
 - 9. Automated refractor.
 - 10. Slit lamp biomicroscope (including methods of examination).
 - 11. Stereo tests.
 - 12. Corneal topographic measurements (placido disc, keratometer, automated corneal topography).
 - 13. Applanation tonometer.
 - 14. Specular microscope.
 - 15. Operating microscope.
 - 16. Zoom lens principle.
 - 17. Corneal pachymeter.
 - 18. Lens screen/Hess chart.
 - 19. Synoptophore.
 - 20. Lenses used for fundus biomicroscopy (panfunduscope, Goldmann lens, Hruby lens, 90 diopter lens, etc.).
 - 21. Fundus camera.
 - 22. Gonioscope.
 - 23. Tonometers.
 - 24. Color vision tests (Ishihara color plates; Hardy-Rand-Rittler plates, Farnsworth-Munsell testing).

Standard Level Goal: PGY-3

Improve proficiency in Basic Level skills.

Advanced Level Goals: PGY-4

Apply, at the highest level of understanding, the relevant optics information in the following situations:

1. Refraction and prescribing of spectacles and contact lenses.
2. Intraocular lens calculation.
3. Cataract surgery.
4. Use of prisms for diplopia.
5. Low vision aid prescribing.

III. Retinoscopy and Refraction

General Educational Objectives:

1. Identify the principles and indications for retinoscopy.
2. Perform the technique of retinoscopy.
3. Identify media opacities with retinoscopy.
4. Perform an integrated refraction based upon retinoscopic results.

Basic Level Goals: PGY-2

1. Describe the major types of refractive errors.
2. Describe basic ophthalmic optics and optical principles of refraction and retinoscopy.
3. Perform retinoscopy for detecting simple refractive errors.
4. Describe the indications for and use trial lenses or a phoropter for simple refractive error.
5. Perform objective and subjective refraction techniques for simple refractive error.
6. Perform elementary refraction techniques (e.g., for myopia, hyperopia, near-vision add).
7. Describe the basic principles of a keratometer.

Standard Level Goals: PGY-3

1. Describe more complex types of refractive errors, including postoperative refractive errors.
2. Perform more advanced refraction techniques (e.g., astigmatism, complex refractions, asymmetric accommodative add).
3. Describe the more advanced ophthalmic optics and optical principles of refraction and retinoscopy (e.g., postkeratoplasty, post-cataract extraction).
4. Perform objective and subjective refraction techniques for more complex refractive errors, including astigmatism and postoperative refractive error.
5. Perform more advanced techniques of retinoscopy for detecting simple and complex refractive error.
6. Describe and use more advanced techniques using trial lenses or the phoropter for more complex refractive errors, including modification and refinement of subjective manifest refractive error and more complex refractive errors (e.g., advanced and irregular astigmatism, vertex distance).
7. Use the keratometer for detection of more advanced refractive error.

Advanced Level Goals: PGY-4

1. Describe the most complex types of refractive errors, including postoperative refractive errors, postkeratoplasty, and refractive surgery.
2. Perform the most advanced refraction techniques (e.g., irregular astigmatism, pre- and post-refractive surgery).
3. Describe the most advanced ophthalmic optics and optical principles of refraction and retinoscopy, including higher order aberrations.
4. Utilize the most advanced ophthalmic optics and optical principles for refraction and retinoscopy, including higher order aberrations.
5. Perform objective and subjective refraction techniques in the most complex refractive error, including astigmatism and postoperative refractive error.
6. Perform the most advanced techniques using trial lenses or the phoropter for more complex refractive errors, including modification and refinement of subjective manifest refractive error, cycloplegic retinoscopy and refraction, and post-cycloplegic refraction, irregular astigmatism, post-keratoplasty, and refractive surgery cases.
7. Use the keratometer for detection of subtle or complex advanced refractive error.
8. Use more advanced refraction instruments and techniques (e.g., distometer, automated refractor, automated corneal topography).

IV. Cataract and Lens

General Educational Objectives:

1. Describe the evaluation and management, indications for, and intraoperative and postoperative complications of cataract surgery and related anterior segment procedures.
2. Perform the complete preoperative ophthalmologic examination of cataract patients.
3. Formulate the differential diagnoses of cataract and evaluate the normal and abnormal lens.
4. Perform optimum refraction of the post-cataract surgery patient.
5. Develop and exercise clinical and ethical decision-making in cataract patients.
6. Develop good patient communication techniques regarding cataract surgery.
7. Perform routine and advanced cataract surgery and intraocular lens (IOL) placement.
8. Manage basic and advanced clinical and surgical cataract problems.
9. Effectively diagnose and manage intraoperative and postoperative complications of cataract surgery.
10. Work effectively as a member of the medical care team.
11. Develop teaching skills about cataract for instructing junior trainees and students.

Basic Level Goals: PGY-2**A. Cognitive Skills**

1. Identify the most common causes and types of cataract (e.g., anterior polar, cortical nuclear sclerotic, posterior subcapsular).
2. List the basic history and examination steps for preoperative cataract evaluation.

3. Describe the steps in cataract surgical procedures.
 4. Define the elementary refraction or contact lens fitting techniques to obtain best corrected vision prior to considering cataract extraction.
 5. Describe the major etiologies of dislocated or subluxated lens (e.g., trauma, Marfan's syndrome, homocystinuria, Weill-Marchesani syndrome, syphilis).
 6. Familiarity with the techniques of intracapsular cataract extraction, extracapsular cataract extraction, and phacoemulsification.
 7. Describe the following:
 - a. Basic ophthalmic optics as related to cataract.
 - b. Types of refractive error in cataract.
 - c. Retinoscopy techniques for cataract.
 - d. Subjective refraction techniques for cataract patients.
 - e. Types of IOLs; IOL power calculation.
 8. Identify and describe the principles and mechanisms of the following instruments in the evaluation of cataract:
 - a. Lensometer.
 - b. Autorefractor.
 - c. Retinoscope.
 - d. Phoropter.
 - e. Keratometer.
 - f. Slit lamp biomicroscope.
 - g. Glare and contrast testing devices.
 - h. Potential acuity meter.
- B. Technical/Surgical Skills**
1. Perform basic slit lamp biomicroscopy, retinoscopy, and ophthalmoscopy.
 2. Evaluate and classify common types of lens opacities.
 3. Perform subjective refraction techniques and retinoscopy in patients with cataract.
 4. Perform direct and indirect ophthalmoscopy pre- and post-cataract surgery.
 5. Perform basic steps of cataract surgery (e.g., incision, wound closure) in the practice lab.
 6. Assist at cataract surgery and perform patient preparation, sterile draping, and anesthesia.
 7. Perform the following steps of cataract surgery in the practice lab or under direct supervision, including any or all of the following:
 - a. Wound construction.
 - b. Anterior capsulotomy/capsulorhexis.
 - c. Instillation and removal of viscoelastics.
 - d. Extracapsular and phacoemulsification techniques (e.g., sculpting, divide & conquer, phaco chop).
 - e. Irrigation and aspiration.
 - f. Cortical clean-up.
 - g. IOL implantation (e.g., anterior and posterior).
- Standard Level Goals: PGY-3**
- A. Cognitive Skills**
1. Describe the less common causes of lens abnormalities (e.g., spherophakia, lenticonus, ectopia lentis).
 2. Describe the preoperative evaluation of the cataract patient, including:
 - a. The systemic diseases of interest or relevance to cataract surgery.
 - b. The relationship of external and corneal diseases of relevance to cataract and cataract surgery (e.g., lid abnormalities, dry eye).
 - c. The relationships of glaucoma, uveitis, and capsular opacities related to cataract surgery.
 3. Describe glare analysis testing for cataract surgery.
 4. Describe the use of A- and B-scan ultrasonography in cataract surgery.
 5. Describe the instruments and techniques of cataract extraction, including extracapsular surgery and phacoemulsification (e.g., trouble-shooting the phacoemulsification machine, altering the machine parameters).
 6. Describe the types, indications, and techniques of anesthesia for cataract surgery (e.g., topical, local, general).
 7. Describe indications, techniques, and complications of surgical procedures, including:
 - a. Extracapsular surgery.
 - b. Intracapsular surgery.
 - c. Phacoemulsification.
 - d. Paracentesis.
 - e. IOL placement.
 8. Describe history and techniques of basic IOL implantation.
 9. Correlate the level of visual acuity with the lens or capsular opacities.
 10. Describe the common complications of cataract and anterior segment surgery (e.g., intraocular pressure elevation, hyphema, endophthalmitis, cystoid macular edema, retinal detachment, intraocular lens dislocation, lens-induced glaucoma, and uveitis).
 11. Describe the indications for, principles of, and techniques of YAG laser capsulotomy, and understand the proper timing of YAG laser capsulotomy.
- B. Technical/Surgical Skills**
1. Perform local injections of corticosteroids, antibiotics, and anesthetics.
 2. Implement the basic preparatory procedures for cataract surgery (e.g., obtaining informed consent, identification of instruments, sterile technique, gloving and gowning, prep and drape, and other preoperative preparation).
 3. Use the operating microscope for basic cataract surgery.
 4. Perform extracapsular surgery in a practice setting (e.g., animal or practice lab) and then in the operating room under supervision, including mastery of the following skills:
 - a. Wound construction.
 - b. Anterior capsulotomy/capsulorhexis.
 - c. Instillation and removal of viscoelastics.
 - d. Extracapsular technique.
 - e. Beginning phacoemulsification techniques (e.g., sculpting, divide & conquer, phaco chop).
 - f. Irrigation and aspiration.
 - g. Cortical clean-up.
 - h. IOL implantation (e.g., anterior and posterior, special IOLs).
 5. Perform paracentesis of the anterior chamber.
 6. Perform the appropriate steps in cataract surgery, assist in cataract surgery, and perform more advanced steps in patient preparation and anesthesia.
 7. Describe the more advanced applications of viscoelastics in surgery (e.g., control of iris prolapse, elevation of dropped nucleus, viscodissection, aspiration of residual/retained viscoelastic).

8. Perform basic postoperative evaluation of the cataract patient.
9. Recognize and refer or treat common postoperative complications of cataract surgery (e.g., endophthalmitis, elevated intraocular pressure, cystoid macular edema, wound leak, uveitis).

Advanced Level Goals: PGY-4

A. Cognitive Skills

1. Define the more complex indications for cataract surgery (e.g., better view of posterior segment), describe the performance of and describe the complications of more advanced anterior segment surgery (e.g., pseudoexfoliation, small pupils, mature cataract, hard nucleus, black cataract, post-traumatic, zonular dehiscence), including more advanced procedures (e.g., secondary IOLs and indications for specialized IOLs, capsular tension rings, iris hooks, use of indocyanine green staining of the anterior capsule).
2. Describe the instruments and techniques of cataract extraction, including extracapsular surgery and phacoemulsification (e.g., trouble-shooting the phacoemulsification machine, altering the machine parameters).
3. Describe the indications for, techniques of, and complications of cataract extraction in the context of the subspecialty disciplines of glaucoma (e.g., combined cataract and glaucoma procedures, glaucoma in cataractous eyes, cataract surgery in patients with prior glaucoma surgery), retina (e.g., cataract surgery in patients with scleral buckles or prior vitrectomy), cornea (e.g., cataract extraction in patients with corneal opacities), ophthalmic plastic surgery (e.g., ptosis following cataract surgery), and refractive surgery (e.g., cataract surgery in eyes that have undergone refractive surgery).
4. Independently evaluate complications of cataract and IOL implant surgery (e.g., posterior capsular tears, vitreous prolapse, intravitreal dislocation of cataractous fragments, choroidal effusions).
5. Understand indications for and technique of intracapsular surgery (e.g., rare cases may require this procedure, or patients may have had the procedure performed previously).
6. Describe indications for and instrumentation and techniques used to implant foldable and non-foldable IOLs.
7. Describe the evaluation and management of common and uncommon causes of postoperative endophthalmitis.
8. Perform repositioning, removal, or exchange of IOLs.
9. Assist in the teaching and supervision of basic and standard level learners (i.e., first and second year residents).
10. Describe the government and hospital regulations that apply to cataract surgery.

B. Technical/Surgical Skills

1. Describe the principles, indications for, mechanics of, and performance of A-scan ultrasonography and calculation of IOL power.
2. Perform phacoemulsification in a practice setting (e.g., animal or practice lab) and then in the operating room, including mastery of the following skills:
 - a. Wound construction.
 - b. Anterior capsulotomy/capsulorhexis.

- c. Viscoelastics.
- d. Intracapsular, extracapsular, and phacoemulsification techniques (e.g., sculpting, divide & conquer, phaco chop, stop and chop).
- e. Instrumentation and techniques of irrigation and aspiration.
- f. IOL implantation (e.g., anterior and posterior, special IOLs).
- g. IOL repositioning, removal or exchange.
3. Perform implantation of foldable and non-foldable IOLs.
4. Perform intraoperative and postoperative management of any event that may occur during or as a result of cataract surgery, including:
 - a. Vitreous loss.
 - b. Capsular rupture.
 - c. Anterior or posterior segment bleeding.
 - d. Positive posterior pressure.
 - e. Choroidal detachments.
 - f. Expulsive hemorrhage.
 - g. Loss of anesthesia.
 - h. Elevated intraocular pressure.
 - i. Use of topical and systemic medications.
 - j. Astigmatism.
 - k. Postoperative refraction (simple and complex).
 - l. Corneal edema.
 - m. Wound dehiscence.
 - n. Hyphema.
 - o. Residual cortex.
 - p. Dropped nucleus.
 - q. Uveitis.
 - r. Cystoid macular edema (CME).
 - s. Elevated intraocular pressure and glaucoma.
 - t. Postoperative early and late intraocular infection.

V. Contact Lens



Basic Level Goals: PGY-2

A. General Educational Objectives

1. Perform a basic contact lens (CL) history and examination, and be aware of additional basic tests and questions that are required for CL patients with more complex needs.
2. Perform the techniques of retinoscopy, refraction, and over-refraction in the routine CL patient.
3. Describe the optics of the soft contact lens and hard contact lens (e.g., rigid gas permeable CL); base curve changes, the lacrimal lens, and the optic zone.
4. Describe conversion of a spectacle prescription (Rx) to a CL Rx, including method of converting from plus to minus cylinder.
5. Describe basic CL design, using appropriate terminology.
6. Describe techniques for and perform basic CL fitting.
7. Describe selection of CL candidates with non-complex needs.
8. Use auxiliary CL instruments and tests (e.g., trial set, fluorescein testing).
9. Perform CL verification for vision correction, fit, and comfort.
10. Describe contraindications for contact lens use.

B. Cognitive Skills

1. Describe fundamentals of ophthalmic optics in CL management (e.g., CL choices, techniques for fitting individuals).
2. List indications for contact lenses in non-complex cases.
3. Describe CL choices and techniques for fitting individuals with non-complex CL needs.

C. Technical/Surgical Skills

1. Perform advanced retinoscopy techniques in a CL patient.
2. Perform advanced refraction techniques in a CL patient, including diagnostic fitting.
3. Perform techniques to verify and inspect contact lenses.
4. Utilize appropriate teaching skills to instruct patients in the safe insertion, removal, and care of contact lenses.

Standard Level Goals: PGY-3**A. General Educational Objectives**

1. Perform a more advanced CL history and examination, employing additional tests and questions appropriate for patients with more complex CL needs (e.g., keratoconus, difficult CL fittings).
2. Perform retinoscopy and refraction in the CL patient with more complex needs (e.g., keratoconus, postkeratoplasty).
3. Describe the more advanced optics of the soft contact lens (SCL) and hard contact lens (e.g., rigid gas permeable CL); base curve changes, the lacrimal lens, and the optic zone.
4. Describe more advanced CL design (e.g., special lenses and special CL shapes or materials).
5. Describe and perform more advanced CL fitting (e.g., postkeratoplasty).
6. Describe selection of CL candidates with more complex needs (e.g., postsurgical).
7. Use auxiliary CL instruments in patients with more complex needs (e.g., postsurgical topography).
8. Perform CL verification for vision, fit, and comfort in therapeutic CL cases.

B. Cognitive Skills

1. Describe more advanced concepts of ophthalmic optics in CL.
2. Describe indications for more advanced CL (e.g., therapeutic lenses).

C. Technical/Surgical Skills

1. Perform more advanced retinoscopy techniques in a CL patient.
2. Perform more advanced refraction techniques in CL patient, including diagnostic fitting.
3. Perform advanced techniques to verify and inspect contact lenses in patients with complex CL needs.
4. Perform more advanced CL fitting in patients with complex needs (e.g., keratoconus, CL in children, active corneal disease).
5. Describe and use the CL instruments in more complex cases.
6. Describe the more advanced CL complications (e.g., microbial keratitis, sterile corneal infiltrates, preservative toxicity).
7. Perform appropriate CL selection (e.g., material selection, CL modification).
8. Perform corneal topography to fit contact lenses.

Advanced Level Goals: PGY-4**A. General Educational Objectives**

1. Perform the most advanced techniques in CL history and examination, and understand what additional tests and questions are needed during the most complex CL examination (e.g., postkeratoplasty, multiple surgery, post-refractive, complex keratoconus fitting, active corneal disease).
2. Perform retinoscopy and refraction in the CL patient with the most complex needs (e.g., keratoglobus, keratoconus, following open globe repair [e.g., corneal laceration] or multiple keratoplasty).
3. Describe the most advanced optics and applications of soft contact lenses and hard contact lenses (e.g., piggyback CL).
4. Describe the most advanced CL design, using appropriate terminology (e.g., special fittings, special lenses for difficult-to-fit patients).
5. Describe indications for and perform the most advanced CL fitting (e.g., post-multiple keratoplasty or traumatic corneal repair).
6. Describe indications for and apply the most complex CL in special circumstances or for candidates presenting increased level of difficulty (e.g., postsurgical patients, children).
7. Use the auxiliary CL instruments in patients with the most complex needs (e.g., topography, fluorescein testing, diagnostic lenses).

B. Cognitive Skills

1. Describe the differences among CL material choices.
2. Describe methods of modifying a contact lens to improve comfort, vision, or physiological response.
3. Evaluate and manage CL-induced complications.
4. Perform and interpret corneal topography in CL fitting.

C. Technical/Surgical Skills

1. Perform CL modification in complex cases.
2. Select the appropriate CL in more complex cases.

VI. Cornea, External Diseases, and Refractive Surgery**Basic Level Goals: PGY-2****A. Cognitive Skills**

1. Describe the basic anatomy, embryology, physiology, pathology, microbiology, immunology, genetics, epidemiology, and pharmacology of the cornea, conjunctiva, sclera, eyelids, lacrimal apparatus, and ocular adnexa.
2. Describe congenital abnormalities of the cornea, sclera, and globe (e.g., Peter's anomaly, microphthalmos, birth trauma, buphthalmos).
3. Describe characteristic corneal and conjunctival degenerations (e.g., pterygium, pinguecula, senile plaques of the sclera, keratoconus).
4. Recognize the common corneal dystrophies and degenerations (e.g., map-dot-fingerprint dystrophy, Meesman dystrophy, Reis-Buckler's dystrophy, Francois syndrome, Schnyder's crystalline dystrophy, congenital hereditary stromal dystrophy, lattice dystrophy, granular dystrophy, macular dystrophy, congenital hereditary endothelial dystrophy, Fuchs' dystrophy, posterior polymorphous dystrophy, Salzmann's degeneration).

5. Recognize the common corneal inflammations and infections (e.g., herpes simplex, herpes zoster, syphilis, interstitial keratitis).
 6. Understand the fundamentals of corneal optics and refraction (e.g., keratoconus).
 7. Describe the fundamentals of ocular microbiology and recognize corneal and conjunctival inflammations and infections (e.g., Staphylococcal hypersensitivity, simple microbial keratitis, trachoma, ophthalmia neonatorum, herpes zoster ophthalmicus, herpes simplex keratitis, and conjunctivitis).
 8. Recognize the basic presentations of ocular allergy (e.g., phlyctenules, seasonal hay fever, vernal conjunctivitis, allergic and atopic conjunctivitis, giant papillary conjunctivitis).
 9. Recognize and treat lid margin disease (e.g., Staphylococcal blepharitis, meibomian gland dysfunction).
 10. Describe the features of, diagnose, and treat (or refer) vitamin A deficiency (e.g., Bitot's spot, dry eye, slowed dark adaptation) and neurotrophic corneal diseases.
 11. Describe the basic differential diagnosis of acute and chronic conjunctivitis or "red eye" (e.g., scleritis, episcleritis, conjunctivitis, orbital cellulitis, gonococcal and chlamydial conjunctivitis).
 12. Describe the basic mechanisms of traumatic and toxic injury to the anterior segment (e.g., alkali burn, lid laceration, orbital fracture, etc.).
 13. Understand the mechanisms of ocular immunology and recognize the external manifestations of anterior segment inflammation (e.g., red eye associated with acute and chronic iritis).
 14. Describe the basic principles of ocular pharmacology of anti-infective, anti-inflammatory and immune modulating agents (e.g., indications and contraindications for topical corticosteroids, non-steroidal anti-inflammatory agents, and antibiotics).
 15. Recognize corneal lacerations (perforating and non-perforating), pterygia that may require surgery, corneal and conjunctival foreign bodies.
 16. Diagnose and treat corneal exposure (e.g., lubrication, temporary tarsorrhaphy).
 17. Describe the epidemiology, differential diagnosis, evaluation and management of common benign and malignant lid lesions, including pigmented lesions of the conjunctiva and lid (e.g., nevi, melanoma, primary acquired melanosis).
 18. Describe the epidemiology, classification, pathology, indications for surgery, and prognosis of common malpositions of the eyelids (e.g., blepharoptosis, trichiasis, distichiasis, essential blepharospasm, entropion, ectropion) and understand their relationship to secondary diseases of the cornea and conjunctiva (e.g., exposure keratopathy).
 19. Recognize and describe the treatment for a chemical burn (e.g., types of agents, medical therapy).
 20. Recognize and describe the etiologies of hyphema and microhyphema.
 21. Describe the etiologies and treatment of superficial punctate keratitis (e.g., dry eye, Thygeson's superficial punctate keratopathy), blepharitis, toxicity, ultraviolet photokeratopathy, contact lens related).
 22. Describe the symptoms and signs, testing and evaluation for, and treatment of exposure keratopathy and dry eye (e.g., Schirmer test).
 23. Recognize the anterior segment manifestations of systemic diseases (e.g., Wilson's disease) and pharmacologic side effects (e.g., amiodarone vortex keratopathy).
 24. Recognize, list the differential diagnosis, and evaluate aniridia and other developmental anterior segment abnormalities (e.g., Axenfeld's, Rieger's, Peter's anomalies and related syndromes).
 25. Recognize and treat pyogenic granuloma.
- B. Technical/Surgical Skills**
1. Perform external examination (illuminated and magnified) and slit lamp biomicroscopy, including drawing of anterior segment findings.
 2. Administer topical anesthesia, as well as special topical stains of the cornea (e.g., fluorescein dye and rose bengal).
 3. Perform simple tests for dry eye (e.g., Schirmer test).
 4. Perform punctal occlusion (temporary or permanent) or insert plugs.
 5. Perform simple corneal sensation testing (e.g., cotton tip swab).
 6. Perform tonometry (e.g., applanation, tonopen, Schiotz, pneumotonometry).
 7. Perform techniques of sampling for viral, bacterial, fungal, and protozoal ocular infections (e.g., corneal scraping and appropriate culture techniques).
 8. Perform and interpret simple stains of the cornea and conjunctiva (e.g., culture techniques, culture media, Gram stain, Giemsa stain, calcofluor white, acid fast).
 9. Manage corneal epithelial defects (e.g., pressure patching and bandage contact lenses).
 10. Perform removal of a conjunctival or corneal foreign body (e.g., rust ring).
 11. Perform primary pterygium excision.
 12. Perform an isolated lid laceration repair.
 13. Perform an isolated corneal laceration repair (e.g., linear laceration not extending to limbus).
 14. Perform epilation.
 15. Perform a lateral tarsorrhaphy.
 16. Incise/drain or remove a primary chalazion/stye.
 17. Perform a simple incisional or excisional biopsy of a lid lesion.
 18. Perform irrigation of chemical burn to the eye.
 19. Treat hyphema and microhyphema (e.g., the complications of increased intraocular pressure and rebleeding).

Standard Level Goals: PGY-3

A. Cognitive Skills

1. Describe the more complex anatomy, embryology, physiology, pathology, microbiology, immunology, genetics, epidemiology, and pharmacology of the cornea, conjunctiva, sclera, eyelids, lacrimal apparatus, and ocular adnexa.
2. Describe the more complex congenital abnormalities of the cornea, sclera, and globe (e.g., hamartomas and choristomas).
3. Describe, recognize, evaluate, and treat peripheral corneal thinning (e.g., inflammatory, degenerative, dellen-related, infectious, immunologic).

4. Recognize common conjunctival neoplasms (e.g., benign, malignant tumors).
 5. Recognize and treat less common corneal or conjunctival presentations of degenerations (e.g., inflamed, atypical, or recurrent pterygium, band keratopathy).
 6. Describe the epidemiology, differential diagnosis, evaluation, and management of Bitot's spots.
 7. Describe the differential diagnosis, evaluation, and management of Thygeson's superficial punctate keratopathy.
 8. Understand more complex corneal optics and refraction (e.g., irregular astigmatism).
 9. Correlate the concordance of the visual acuity with the density of media opacity (e.g., cataract) and evaluate the etiology of discordance between acuity and findings from examination of the media.
 10. Describe more complex ocular microbiology and describe the differential diagnosis of more complicated corneal and conjunctival infections (e.g., complex, mixed, or atypical bacterial, fungal, *Acanthamoeba*, viral, or parasitic keratitis).
 11. Describe differential diagnosis, evaluation, and treatment of interstitial keratitis (e.g., syphilis, viral diseases, non-infectious, immunologic, inflammation).
 12. Describe more complex differential diagnosis of the "red eye" (e.g., autoimmune and inflammatory disorders causing scleritis, episcleritis, conjunctivitis, orbital cellulitis).
 13. Describe key features of trachoma, including epidemiology, clinical features and staging, and its complications (e.g., cicatrization), prevention (e.g., facial hygiene), and topical and systemic antibiotic treatment (especially in hyperendemic regions), and surgery (e.g., tarsal rotation).
 14. Describe more complex mechanisms of traumatic and toxic injury to the anterior segment (e.g., long-term sequelae of acid and alkali burn, complex lid laceration involving the lacrimal system, full-thickness laceration).
 15. Describe the differential diagnosis and the external manifestations of more complex anterior segment inflammation (e.g., acute and chronic iritis with and without systemic disease).
 16. Describe the more complex principles of ocular pharmacology of anti-infective, anti-inflammatory and immune modulating agents (e.g., use of topical nonsteroidal and steroidal agents, topical cyclosporine).
 17. Recognize and treat corneal lacerations (perforating and non-perforating).
 18. Recognize and treat large, recurrent, or atypical pterygia that may require surgery.
 19. Describe and treat corneal and conjunctival foreign bodies.
 20. Diagnose and treat severe corneal exposure (e.g., lubrication, temporary tarsorrhaphy).
 21. Recognize and treat common and uncommon benign and malignant lid lesions.
 22. Recognize and treat common malpositions of the eyelids (e.g., entropion, ectropion, and ptosis) as they apply to secondary corneal disease.
 23. Recognize and treat recurrent corneal erosions.
 24. Recognize and treat foreign body, animal, and plant substance injuries.
 25. Recognize and treat more complex hyphemas (e.g., surgical indications).
 26. Recognize, evaluate, and treat chronic conjunctivitis (e.g., chlamydia, trachoma, molluscum contagiosum, Parinaud's oculoglandular syndrome, ocular rosacea).
 27. Describe the clinical features, pathology, evaluation, and treatment of ocular cicatricial pemphigoid.
 28. Recognize, evaluate, and treat the ocular complications of severe diseases, such as chronic exposure keratopathy, contact dermatitis, and Stevens-Johnson syndrome.
 29. Describe the epidemiology, clinical features, pathology, evaluation, and treatment of peripheral corneal thinning or ulceration (e.g., Terrien's marginal degeneration, Mooren's ulcer, rheumatoid arthritis-related corneal melt).
- B. Technical/Surgical Skills**
1. Perform more advanced techniques, including keratometry, keratoscopy, endothelial cell count and evaluation, specular microscopy, and pachymetry.
 2. Perform stromal micropuncture.
 3. Perform application of corneal glue.
 4. Assist in more complex corneal surgery (e.g., penetrating keratoplasty and phototherapeutic keratectomy).
 5. Perform more advanced tests for dry eye (e.g., modified Schirmer tests, assessment of tear break-up time, fluorescein dye testing, rose bengal dye).
 6. Perform more complex pterygium excision, including conjunctival grafting.
 7. Perform more complex lid laceration repair.
 8. Perform manual superficial or lamellar keratectomy.
 9. Perform more complex corneal laceration repair (e.g., stellate perforating laceration).
 10. Repair simple lacerations of the lacrimal drainage apparatus (e.g., perform intubations and primary closure).

Advanced Level Goals: PCY-4

A. Cognitive Skills

1. Describe the most complex anatomy, embryology, physiology, histopathology, microbiology, immunology, genetics, epidemiology, and pharmacology of the cornea, conjunctiva, sclera, eyelids, lacrimal apparatus, and ocular adnexa.
2. Describe the most complex and less common congenital abnormalities of the cornea, sclera, and globe (e.g., cornea plana, keratoglobus).
3. Recognize common and uncommon corneal and conjunctival neoplasms, dystrophies and degenerations (e.g., lattice dystrophy).
4. Understand the most complex corneal optics and refraction (e.g., postkeratoplasty).
5. Describe less common and rare ocular infections and describe the differential diagnosis of the most complicated corneal and conjunctival infections (e.g., amoebas, leishmaniasis, nematodes).
6. In non-endemic areas, describe the basic features of onchocerciasis.
7. In endemic areas, define the etiology, vector (e.g., black fly), and incidence, diagnostic features (e.g., microfilariae, keratitis, iritis), diagnosis (e.g., skin snip test), course and prognosis, treatment (e.g., ivermectin, nodulectomy), and prevention (e.g., vector control, environmental and behavioral changes) of onchocerciasis.

8. Describe the most complex differential diagnosis of the "red eye" (e.g., pemphigoid, pemphigus, Stevens Johnson syndrome).
 9. Diagnose and treat the most complex traumatic and toxic injuries to the anterior segment (e.g., total lid avulsion, severe alkali burn).
 10. Describe the differential diagnosis and the external manifestations of the most complex or uncommon anterior segment inflammations (e.g., syphilitic keratouveitis).
 11. Describe the most complex principles of ocular pharmacology of anti-infective, anti-inflammatory and immune modulating agents (e.g., combination therapies of antiviral and anti-inflammatory agents).
 12. Recognize and treat complex corneal lacerations (e.g., lacerations extending beyond the limbus).
 13. Diagnose and treat the most severe corneal exposure cases (e.g., conjunctival flap).
 14. Understand ocular surface transplantation, including conjunctival autograft/flap, amniotic membrane transplantation, limbal stem cell transplantation.
 15. Understand the surgical indications (e.g., Fuchs' dystrophy, aphakic/pseudophakic bullous keratopathy), surgical techniques, and recognition and management of postoperative complications (especially immunologically-mediated rejection) of corneal transplantation (e.g., penetrating, lamellar).
 16. Understand the preoperative assessment, patient selection, surgical management, and postoperative care of refractive surgical techniques, including keratotomy (radial, astigmatic), photoablation (photorefractive, phototherapeutic, LASIK), corneal wedge resection, thermokeratoplasty, intracorneal rings, phakic intraocular lens, and clear lens extraction.
- B. Technical/Surgical Skills**
1. Perform and interpret the most advanced corneal techniques (e.g., pachymetry, endothelial microscopy, computerized corneal topography).
 2. Understand and perform specialized and complicated contact lens fitting (e.g., post-keratoplasty).
 3. Perform more complex corneal surgery (e.g., penetrating or lamellar keratoplasty, keratorefractive procedures, and phototherapeutic keratectomy).
 4. Repair complex entropion and ectropion.
 5. Perform a thin conjunctival flap (e.g., Gunderson flap).
 6. Perform other complex conjunctival surgery (e.g., autograft, stem cell transplant).
 7. Perform basic non-laser refractive surgery techniques (e.g., relaxing keratotomy).
 8. Manage and treat more complex neoplasms of the conjunctiva (e.g., carcinoma, melanoma).
 4. Describe basic tonometry and understand the principles of tonography.
 5. Describe optic nerve and nerve fiber layer anatomy in glaucoma.
 6. Describe fundamentals of perimetry, including kinetic and automated static perimetry.
 7. Describe principles, indications, and basic techniques of gonioscopy, including normal and abnormal findings.
 8. Describe principles of medical management, including indications for and side effects of treatment options (e.g., topical and systemic medications) for simple glaucoma (e.g., POAG, primary angle closure glaucoma).
 9. Describe and recognize normal tension glaucoma ("low tension glaucoma").
 10. Describe the features of and recognize primary and secondary angle closure glaucoma and aqueous misdirection.
 11. Recognize hypotony and describe the clinical features (e.g., Seidel test for transconjunctival leakage).
 12. List the main results of the major clinical trials in glaucoma (e.g., Glaucoma Laser Trial, Normal Tension Glaucoma Study, and Advanced Glaucoma Intervention Study [see **XVIII. Literature and Studies for Review for references**]).
- B. Technical/Surgical Skills**
1. Perform basic tonometry (e.g., applanation, Schiötz [if applicable], tonopen, airpuff) and recognize the pitfalls and artifacts of the testing.
 2. Perform basic gonioscopy (e.g., recognize angle structures, identify angle closure).
 3. Perform stereo examination of the optic nerve, using 90 diopter or other lens.
 4. Interpret manual (e.g., Goldmann) and automated (e.g., Humphrey, Octopus) visual fields in routine glaucoma.
 5. Perform corneal pachymetry and relate the findings to interpretation of intraocular pressure.

Standard Level Goals: PGY-3

A. Cognitive Skills

1. Describe the epidemiology and perform screening for routine and more advanced primary and secondary open angle glaucoma.
2. Describe the treatment of disturbances of aqueous humor dynamics.
3. Describe the more complex etiologies for, evaluation of, and treatment of glaucoma (e.g., angle recession, inflammatory, steroid-induced, pigmentary, pseudoexfoliative, phacolytic, neovascular, postoperative, malignant, lens particle glaucomas; plateau iris; glaucomatocyclitic crisis; iridocorneal endothelial syndromes; aqueous misdirection).
4. Describe more advanced tonometric and tonographic (if applicable) methods (e.g., diurnal curve).
5. Describe more advanced optic nerve and nerve fiber layer anatomy in primary and secondary glaucoma and recognize typical and atypical features associated with glaucomatous cupping (e.g., rim pallor, rapid progression, central acuity loss, hemianopic or other non-glaucomatous types of visual field loss).
6. Describe more advanced forms of perimetry (e.g., kinetic and automated static visual fields) and perimetry strate-

VII. Glaucoma



Basic Level Goals: PGY-2

A. Cognitive Skills

1. Describe the epidemiology and genetics of primary open angle glaucoma (POAG).
2. Perform evaluation of POAG.
3. Describe the mechanics of aqueous humor dynamics and the anatomy of the anterior chamber and its angle, and of the ciliary body.

- gies (e.g., threshold testing, supra-threshold testing, special algorithms).
- Describe the principles, indications, and more advanced anatomic findings and gonioscopic features of primary and secondary glaucomas (e.g., plateau iris, appositional closure).
 - Describe the principles of medical management of more advanced glaucomas (e.g., advanced POAG, secondary open and closed angle glaucomas, normal tension glaucoma).
 - Describe the features of, recognize, and treat primary angle closure glaucoma and aqueous misdirection.
 - Describe the clinical features of, recognize, and treat less common etiologies of ocular hypotony.
 - Describe the results and apply the conclusions to clinical practice of the major clinical trials in glaucoma (e.g., Glaucoma Laser Trial, Normal Tension Glaucoma Study, and Advanced Glaucoma Intervention Study [see more complete list of clinical trial references in section XVIII. Literature and Studies for Review]).
 - Recognize and treat the various adult secondary glaucomas.
 - Describe the features of primary infantile and juvenile glaucomas.
 - Describe and apply specific medical treatments of more advanced glaucoma.
 - Describe the principles of laser treatments of glaucoma (e.g., indications, techniques, and complications, and use of various types of laser energy, spot size, laser wavelengths).
 - Describe the surgical treatment of glaucoma (e.g., trabeculectomy, combined cataract and trabeculectomy, setons, and cyclodestructive procedures, including indications, techniques, and complications).
- B. Technical/Surgical Skills**
- Perform YAG laser posterior capsulotomy for uncomplicated posterior capsule opacity.
 - Perform argon or YAG laser peripheral iridotomy for routine angle closure glaucoma.
 - Perform argon laser trabeculoplasty.
 - Perform cyclophotocoagulation.
 - Perform routine first trabeculectomy with or without antimetabolites.
 - Describe and manage a flat anterior chamber.
 - Perform routine revision of filtering blebs.
- Advanced Level Goals: PGY-4**
- A. Cognitive Skills**
- Describe the features of the most complex and most advanced forms of primary and secondary open angle glaucoma.
 - Describe the mechanics of aqueous humor dynamics in the most advanced and complex etiologies of glaucoma (e.g., angle recession, combined or multifactorial glaucoma, traumatic or inflammatory glaucoma, pigmentary dispersion glaucoma).
 - Apply in clinical practice tonometric and tonographic methods (e.g., diurnal curve) in complicated or atypical cases of glaucoma.
 - Apply the most advanced knowledge of optic nerve and nerve fiber layer anatomy and describe techniques, methods, and tools for analyzing the nerve fiber layer.
 - Recognize and evaluate atypical or multifactorial glaucomatous cupping (e.g., rim pallor).
 - Describe, interpret, and apply the results of the most complex and advanced forms of perimetry, including special kinetic and automated static perimetry strategies (e.g., special algorithms) in atypical or multifactorial glaucoma.
 - Describe the principles and indications, and apply to clinical practice, the findings of gonioscopy in the most complex primary and secondary glaucomas.
 - Describe the principles of medical management of the most advanced and complex glaucoma (e.g., advanced POAG previously treated with medicine, laser or surgery; secondary glaucomas).
 - Describe, recognize, and treat the most advanced cases of primary open angle glaucoma (e.g., monocular patients, repeat surgical cases), normal tension glaucoma, and secondary glaucomas (e.g., inflammatory glaucoma, angle recession).
 - Describe the features of, recognize, and treat the most advanced cases of primary angle closure glaucoma and complex glaucomas (e.g., postoperative cases, secondary angle closure, aqueous misdirection).
 - Describe the clinical features of ocular hypotony, and recognize and treat common and uncommon etiologies (e.g., choroidal detachment, leaking trabeculectomy bleb).
 - Describe the results, apply the conclusions, and critically analyze the major clinical trials in glaucoma (e.g., Glaucoma Laser Trial, Normal Tension Glaucoma Study, and Advanced Glaucoma Intervention Study), as well as describe and use other publications in the management of glaucoma patients (see XVIII. Literature and Studies for Review for references).
 - Recognize and treat uncommon adult secondary glaucomas.
 - Describe the features of and treat or refer the primary infantile and juvenile glaucomas.
 - Describe and apply specific medical treatments in the most complex and most advanced glaucoma cases (e.g., refractory glaucoma, monocular patients, non-compliant patients).
 - Describe the principles, indications, and complications of laser treatment of more advanced or complex glaucoma (repeat procedures).
 - Describe the more advanced surgical treatment of glaucoma: (e.g., trabeculectomy, combined cataract and trabeculectomy, setons, and cyclodestructive procedures, including indications, techniques, and complications).
- B. Technical/Surgical Skills**
- Perform YAG or argon laser procedures in glaucoma patients (e.g., monocular patient, repeat laser, vitreous lysis, suture lysis).
 - Perform laser peripheral iridotomy for more advanced glaucoma (e.g., monocular patient, acute angle closure, hazy cornea).
 - Perform laser treatments (e.g., argon laser trabeculoplasty, iridoplasty) for more advanced glaucoma cases (repeat treatments, monocular patient).

4. Perform cyclophotocoagulation for more advanced cases (e.g., prior surgery, monocular).
5. Perform routine and repeat trabeculectomy with or without antimetabolites.
6. Describe, manage, and treat surgically, if necessary, a flat anterior chamber.
7. Perform more advanced techniques for the revision of filtering blebs (e.g., failing bleb, leaking bleb).
8. Recognize and treat complications of glaucoma surgery blebs.

VIII. Neuro-Ophthalmology



Basic Level Goals: PCY-2

A. Cognitive Skills

1. Describe the neuro-anatomy of the visual pathways.
2. Describe the neuro-anatomy of the cranial nerves.
3. Describe the pupillary and accommodative neuro-anatomy.
4. Describe ocular motility and related neuronal pathways.
5. Describe the typical features, evaluation, and management of the most common optic neuropathies (e.g., demyelinating optic neuritis, ischemic optic neuropathy [arteritic and non-arteritic], toxic or nutritional optic neuropathy, Leber's hereditary optic neuropathy, ethambutol toxicity, neuroretinitis, and compressive, inflammatory, infiltrative, and traumatic optic neuropathies).
6. Describe the typical features, evaluation, and management of the most common ocular motor neuropathies (e.g., third, fourth, sixth nerve palsy).
7. Describe the typical features of cavernous sinus and superior orbital fissure syndromes (e.g., infectious, vascular, neoplastic, inflammatory etiologies).
8. Describe the typical features, evaluation, and management of the most common causes of nystagmus (e.g., congenital motor and sensory, downbeat, upbeat, gaze-evoked, drug-induced).
9. Describe the typical features, evaluation, and management of the most common pupillary abnormalities (e.g., relative afferent pupillary defect, anisocoria, Horner's syndrome, third nerve palsy, Adie's tonic pupil).
10. Describe the typical features, evaluation, and management of the most common visual field defects (e.g., optic nerve, optic chiasm, optic radiation, occipital cortex).
11. Describe the clinical features, evaluation, and management of ocular myasthenia gravis.
12. Describe the clinical features, evaluation, and management of carotid-cavernous fistula.
13. Describe the differential diagnosis, evaluation and management of congenital optic nerve abnormalities (e.g., optic pit, disc coloboma, papillorenal syndrome, morning glory syndrome, tilted disc, optic nerve hypoplasia, myelinated nerve fiber layer, melanocytoma, disc drusen, Bergmeister's papilla).

B. Technical/Surgical Skills

1. Perform a basic pupillary examination:
 - a. Describe indications for and perform basic pharmacologic pupillary testing for Horner's syndrome, pharmacologic dilation, and Adie's tonic pupil.

- b. List the differential diagnosis of anisocoria (e.g., sympathetic or parasympathetic lesion, "physiologic" or normal).
 - c. Describe, detect, and quantitate a relative afferent pupillary defect.
 - d. List the causes for light-near dissociation (e.g., Argyll-Robertson pupils, diabetic neuropathy, tonic pupil).
2. Perform a basic ocular motility examination:
 - a. Assess ocular alignment using simple techniques (e.g., Hirschberg test, Krimsky method).
 - b. Describe and perform basic cover/uncover testing for tropia.
 - c. Describe and perform alternate cover testing for phoria.
 - d. Perform simultaneous prism and cover testing.
 - e. Perform measurement of deviations with prisms.
 - f. Describe the indications for and apply Fresnel and grind-in prisms.
 - g. Describe the indications for and perform forced duction and forced generation testing.
 - h. Perform an assessment of saccade accuracy and pursuit and optokinetic testing.
 - i. Perform a measurement of eyelid function (e.g., levator function, lid position).
3. Describe the indications for visual field testing and perform and interpret perimetry studies:
 - a. Perform confrontational field testing (static and kinetic, central and peripheral, red and white targets).
 - b. Perform and interpret a tangent screen test.
 - c. Describe the indications for and perform basic Goldmann perimetry, and interpret results.
 - d. Describe the indications for and perform basic automated perimetry, and interpret results.
4. Perform basic direct, indirect, and magnified ophthalmoscopic examination of the optic disc (e.g., recognize optic disc swelling, optic atrophy, neuroretinitis).
5. Describe the anatomy and indications for, order appropriately, and interpret basic radiology studies of the brain and orbits, demonstrating the ability to communicate with radiologists in order to maximize both choice of proper diagnostic test and accuracy of interpretation.
6. Describe the indications for and interpret basic echography of orbits.

Standard Level Goals

A. Cognitive Skills

1. Describe typical and atypical features, evaluation, and management of the most common optic neuropathies (e.g., papilledema, optic neuritis, ischemic, inflammatory, infectious, infiltrative, compressive, and hereditary optic neuropathies).
2. Describe typical and atypical features, evaluation, and management of the more complex supranuclear and internuclear palsies and less common ocular motor neuropathies (e.g., progressive supranuclear palsy and internuclear ophthalmoplegia).
3. Describe typical and atypical features, evaluation, and management of the more complex and less common forms of nystagmus (e.g., rebound, convergence, retraction).
4. Describe typical and atypical features, evaluation, and management of the more complex and less common pu-

- pillary abnormalities (e.g., light-near dissociation, pharmacologic miosis).
- Describe typical and atypical features, evaluation, and management of the more complex and less common visual field defects (e.g., lateral geniculate, monocular temporal crescent).
 - Describe more advanced aspects of visual field indications, selection, and interpretation (e.g., artifacts of automated perimetry, testing and thresholding strategies).
 - Describe neuro-ophthalmic aspects of common systemic diseases (e.g., hypertension, diabetes, thyroid disease, myasthenia gravis, temporal arteritis, systemic infections and inflammation).
 - Describe neuro-ophthalmologic findings in trauma (e.g., traumatic optic neuropathy, traumatic brain injury).
 - Describe typical features of inherited neuro-ophthalmologic diseases (e.g., Leber's hereditary optic neuropathy, autosomal dominant optic atrophy, spinocerebellar degenerations).
 - Recognize, evaluate, and treat ocular myasthenia gravis.
- B. Technical Skills**
- Describe the indications for, administer, and interpret the results of intravenous edrophonium (Tensilon) and Prostigmin tests for myasthenia gravis.
 - Perform a detailed cranial nerve evaluation (e.g., testing of oculomotor, trochlear, trigeminal, and facial nerve function).
 - Describe the more advanced interpretation of neuro-radiologic images (e.g., indications and interpretation of orbital tumors, thyroid eye disease, pituitary adenoma, optic nerve glioma, optic nerve sheath meningioma).
 - Describe the evaluation, management, and specific testing (e.g., stereopsis, mirror test, red-green testing) of patients with "functional" (non-organic) visual loss (e.g., recognize non-organic spiral or tunnel visual fields).
 - Describe the indications for, perform, and list the complications of temporal artery biopsy.
 - Describe the most advanced aspects of visual field indications, selection, and interpretation (e.g., variability in automated perimetry, application of specific testing and thresholding strategies for different patient populations with different neuro-ophthalmic conditions, different testing abilities (e.g., young or old age, mental status, hand-eye coordination, reaction time).
 - Describe, evaluate, and treat the neuro-ophthalmic aspects of systemic diseases (e.g., malignant hypertension, diabetic papillopathy, toxicity of systemic medications, pseudotumor cerebri).
 - Describe, evaluate, and treat the neuro-ophthalmologic manifestations of trauma (e.g., corticosteroid or surgical therapy in traumatic optic neuropathy).
 - Describe, evaluate, and provide appropriate genetic counseling for neuro-ophthalmologic diseases (e.g., Leber's hereditary optic neuropathy, chronic progressive external ophthalmoplegia, von Hippel-Lindau syndrome).
 - Recognize, evaluate, and treat (or refer) more complex forms of nystagmus.
 - Recognize, evaluate, and treat (or refer) transient monocular or binocular visual loss.
- B. Technical/Surgical Skills**
- Perform and interpret the results of the intravenous edrophonium (Tensilon) and prostigmine tests for myasthenia gravis, and recognize and treat the complications of the procedures.
 - Perform and interpret the complete cranial nerve evaluation and basic neurologic examination in the context of neuro-ophthalmic localization and diseases.
 - Interpret neuro-radiologic images in neuro-ophthalmology (e.g., interpretation of orbital imaging for orbital pseudotumor and tumors, thyroid eye disease, intracranial imaging modalities and strategies for tumors, aneurysms, infection, inflammation, and ischemia), and appropriately discuss, in advance of testing, the localizing clinico-radiologic features with the neuroradiologist in order to obtain the best study and interpretation of the results.
 - Recognize patients with "functional" visual loss (non-organic visual loss) and provide appropriate counseling and follow-up.

Advanced Level Goals

A. Cognitive Skills

- Describe typical and atypical features, evaluation, and management of the most advanced and least common optic neuropathies (e.g., chronic or recurrent optic neuritis, and posterior ischemic, autoimmune, toxic/nutritional).
- Describe typical and atypical features, evaluation, and management of the most complex and least common ocular motor neuropathies and their mimics (e.g., progressive supranuclear palsy).
- Describe typical and atypical features, evaluation, and management of the most complex and least common forms of nystagmus (e.g., surgical treatment options, using the null point in either prism or surgical therapy).
- Describe typical and atypical features, evaluation, and management of the most advanced and least common pupillary abnormalities (e.g., pupil findings in coma, transient pupillary phenomenon).
- Describe typical and atypical features, evaluation, and management of the most complex and least common visual field defects (e.g., combination or bilateral lesions, cortical visual impairment).

IX. Ophthalmic Histopathology



Basic Level Goals: PGY-2

A. Cognitive Skills

- Describe basic ocular anatomy and identify the histology of the major structures of the eye (e.g., conjunctiva, sclera, cornea, anterior chamber angle, iris, ciliary body, lens, vitreous, retina, retinal pigment epithelium, choroid, optic nerve).
- Describe basic pathophysiology of the common disease processes of the eye and identify the major histologic findings of each (e.g., infection, inflammation, neoplasm).
- Identify the histology of important intraocular and adnexal diseases (e.g., endophthalmitis, retinoblastoma, choroidal melanoma, microbial keratitis).

B. Technical Skills (for an ocular pathology laboratory, as available)

- Describe appropriate steps in the basic handling and processing of gross specimens in the ocular pathology

- laboratory (e.g., basic preparation of the specimen) and demonstrate proficiency in these steps in the laboratory.
2. Describe specific information necessary for communication with the pathologist regarding special handling of specimens for special stains or studies.
3. Describe indications for frozen sections in ocular pathology.
4. Perform cutting and gross examination of whole globes.
5. Participate under supervision in the microscopic examination of ophthalmology specimens from active cases.

Standard Level Goals: PGY-3

A. Cognitive Skills

1. Describe more advanced ocular anatomy and identify the histology of the major and minor structures of the eye (e.g., conjunctival glands, normal pigment, common variants).
2. Describe more advanced pathophysiology of the disease processes of the eye and identify the major histologic findings of each (e.g., fungal keratitis, skin and adnexal neoplasms, and less common intraocular tumors).
3. Identify histology of the less common but potentially vision or life threatening intraocular and adnexal diseases (e.g., temporal arteritis, fungal endophthalmitis, extraocular spread of intraocular tumor, metastatic disease to the eye).
4. Describe more advanced techniques in ocular histopathology (e.g., electron microscopy, cytology, immunohistochemistry, flow cytometry, tumor free margins).

B. Technical/Surgical Skills

1. Describe appropriate steps in the more advanced handling and special processing of gross specimens in the ocular pathology laboratory.
2. Describe specific indications for special handling and communicate to the pathologist the necessity for special handling of specimens for special stains or studies (e.g., electron microscopy, immunohistochemistry, flow cytometry, cytology).
3. Describe indications and perform and prepare a biopsy specimen for frozen section in ocular pathology.
4. Prepare a basic histologic specimen for review by the pathologist.
5. Participate as an “at-the-elbow” observer during microscopic examination of active ophthalmology cases and perform microscopic examination of a specimen with and without direct supervision.

Advanced Level Goals: PGY-4

A. Cognitive Skills

1. Describe the most advanced ocular anatomy and identify histology of the major and minor structures of the eye and their less common “normal” variants (e.g., pars plana cysts, iris heterochromia, cobblestone degeneration of the retina).
2. Describe the most advanced, less common, or more complex pathophysiology of the disease processes of the eye and identify major histologic findings of each (e.g., inflammatory pseudotumor, lymphoma, artifacts of processing).

3. Identify the histology of the least common but potentially vision or life threatening intraocular and adnexal diseases (e.g., healed giant cell arteritis, mimics and masqueraders of inflammation or neoplasm, uncommon benign and malignant neoplasms).

B. Technical/Surgical Skills

1. Describe and perform appropriate steps for handling gross or cytologic specimens in the ocular pathology laboratory.
2. Perform preoperative, intraoperative, and postoperative consultation with the pathologist, regarding specific indications for special stains or processing (e.g., orientation of specimen, special handling).
3. Perform and interpret the pathologic report of frozen section in ocular pathology.
4. Perform the preparation of basic and more advanced histologic specimens for review by the pathologist (e.g., simple or special stains or fixation methods).
5. Participate as an “at-the-elbow” observer during the microscopic examination of active ophthalmology cases.
6. Perform microscopic examination of a specimen with and without direct supervision and provide a relevant differential diagnosis.

X. Oculoplastic Surgery and Orbit



Basic Level Goals (PGY-2)

A. Cognitive Skills

1. Describe basic eyelid, lacrimal, and orbital anatomy and physiology (e.g., eyelid, orbicularis, orbital structures, meibomian glands, lacrimal glands, Zeis glands, Whittall's ligament, Muller's muscle, Lockwood's ligament, canaliculi, puncta, orbital bones, orbital foramina, paranasal sinuses, annulus of Zinn, arterial and venous vascular supply, lymphatics, nerves, extraocular muscles).
2. Describe basic mechanisms and indications for treatment of eyelid, orbital, and lacrimal trauma.
3. Describe epidemiology, clinical features, evaluation, and management of fetal alcohol syndrome.
4. Perform preoperative and postoperative assessment of patients with common oculoplastic disorders.
5. Recognize simple orbital trauma (e.g., orbital foreign body, retrobulbar hemorrhage).
6. Recognize and treat floppy eyelid syndrome.
7. Recognize and treat localized trichiasis.
8. Recognize blepharospasm and hemifacial spasm.
9. Describe the differential diagnosis of common orbital tumors in children and adults.
10. Describe the differential diagnosis of lacrimal gland mass (e.g., inflammatory, neoplastic, congenital, infectious).
11. Identify normal orbital anatomy on imaging studies (e.g., magnetic resonance imaging, computed tomography, ultrasound).
12. Describe the differential diagnosis of proptosis in children and adults.
13. Describe techniques and complications of minor operating room procedures (e.g., incision and drainage of chalazia, excision of small eyelid lesions).
14. Describe typical features of orbital cellulitis.

B. Technical/Surgical Skills

1. Describe indications for and perform the basic office examination techniques for the most common oculoplastic and orbital abnormalities.
2. Perform the basic assessment of the eyelids, eyebrows, and eyelashes (e.g., eversion, double eversion, margin to reflex distance, lid crease, levator function, eyelid/brow malpositions).
3. Identify indications for and perform the basic lacrimal assessment (e.g., dye testing, punctal dilation, canalicular probing, lacrimal irrigation).
4. Identify indications for and perform the basic assessment of the orbit (e.g., Hertel exophthalmometry, inspection, palpation, auscultation).
5. Identify indications for and perform the basic socket assessment (e.g., types of implants, socket health).
6. Perform minor lid and conjunctival procedures (e.g., removal of benign eyelid skin lesions, chalazion curettage or excision, conjunctival biopsy).
7. Treat complications of minor operating room procedures (e.g., incision and drainage of chalazia, excision of small eyelid lesions).
8. Perform punctal plug insertion or removal.
9. Recognize and treat trichiasis (e.g., epilation, cryotherapy, surgical therapy).
10. Perform a simple enucleation or evisceration under supervision.

Standard Level Goals: PGY-3

A. Cognitive Skills

1. Describe more advanced eyelid, lacrimal, and orbital anatomy and physiology (e.g., lacrimal apparatus, orbital vascular anatomy).
2. Describe the genetics (where known), clinical features, evaluation, and treatment of congenital eyelid deformities (e.g., coloboma, distichiasis, epicanthus, telecanthus, blepharophimosis, ankyloblepharon, epiblepharon, euryblepharon, and Goldenhar syndrome, Treacher-Collins syndrome, Waardenburg syndromes).
3. Describe the clinical features, evaluation and management of congenital orbital deformities (e.g., synophthalmia, anophthalmia, microphthalmia, cryptophthalmia, hypertelorism, hypotelorism).
4. Describe the genetics, clinical features, evaluation, and management of common craniosynostoses and other congenital malformations (e.g., Crouzon and Apert syndromes).
5. Treat (or refer for treatment) congenital eyelid abnormalities (see Basic Level, above).
6. Perform preoperative and postoperative assessment of patients with simple and more serious oculoplastic disorders (e.g., multi-disciplinary procedures).
7. Describe the mechanisms and indications for treatment of more advanced eyelid, orbital, and lacrimal trauma (e.g., full thickness lid laceration, chemical burns to the face).
8. Describe features of, evaluate, and treat more complicated cases of nasolacrimal duct obstruction, canaliculitis, dacryocystitis, acute and chronic dacryoadenitis, preseptal cellulitis, and orbital cellulitis.

9. Recognize, evaluate and treat thyroid ophthalmopathy (e.g., epidemiology, symptoms and signs, associated systemic diseases, orbital imaging, differential diagnosis, surgical, medical and radiation indications, side effects of treatment).
10. Recognize, evaluate, and treat orbital inflammatory pseudotumor (e.g., symptoms and signs, orbital imaging, differential diagnosis, biopsy indications, choice of treatments).
11. Recognize, treat, or refer blepharospasm or hemifacial spasm.
12. Recognize less common orbital tumors (e.g., metastatic lesions).

B. Technical/Surgical Skills

1. Describe indications for and perform more advanced examination techniques for less common oculoplastic and orbital abnormalities (e.g., measurement of levator function, orbital ultrasound interpretation).
2. Identify indications for and perform more advanced assessment of eyelids and eyebrows (e.g., hypoglobus, facial asymmetry, brow ptosis).
3. Identify indications for and perform more advanced lacrimal assessment (e.g., interpretation of dye testing, canalicular probing in trauma).
4. Identify indications for and perform more advanced assessment of the orbit (e.g., enophthalmus, interpretation of orbital ultrasound in common conditions).
5. Identify indications for and perform more advanced socket assessment (e.g., extrusion of implants, anophthalmic socket complications).
6. Perform more complicated minor lid procedures (e.g., larger benign skin lesions) or surgery (e.g., recurrent or multiple chalazion).
7. Recognize the indications and complications and perform more complex minor operating room or limited operating room procedures (e.g., incision and drainage of recurrent or larger chalazia, excision of moderate sized benign eyelid lesions).
8. Recognize and treat orbital trauma (e.g., intraorbital foreign body, retrobulbar hemorrhage, fracture).
9. Identify common orbital pathology (e.g., orbital fractures, orbital tumors) on imaging studies (e.g., magnetic resonance imaging, computed tomography, ultrasound).
10. Treat common presentations of preseptal or orbital cellulitis.
11. Describe, recognize the indications for and complications of, and perform the basic lacrimal procedures below:
 - a. Lacrimal drainage testing (irrigation, dye disappearance test).
 - b. Lacrimal intubation.
 - c. Dacryocystorhinostomy (external).

Advanced Level Goals: PGY-4

A. Cognitive Skills

1. Describe the most advanced eyelid, lacrimal, and orbital anatomy and physiology.
2. Evaluate and treat simple and more advanced eyelid, orbital, and lacrimal trauma (e.g., full thickness lid laceration, chemical burns to the face).
3. Perform preoperative and postoperative assessment and coordination of care of patients with more advanced or

- complex oculoplastic disorders (e.g., systemically ill patients, multi-disciplinary procedures).
4. Describe the etiology, evaluation, and medical and surgical treatment of the following eyelid diseases:
 - a. Complex ectropion (e.g., congenital, paralytic, involutional, cicatricial, mechanical, allergic).
 - b. Complex entropion (e.g., involutional, cicatricial, spastic, congenital).
 - c. Complex myogenic ptosis (e.g., chronic progressive external ophthalmoplegia).
 - d. Complex differential diagnosis for dermatochalasis (e.g., blepharochalasis).
 - e. Benign, pre-malignant, or malignant eyelid tumors (e.g., papilloma, keratoacanthoma, seborrheic keratosis, epidermal inclusion cyst, molluscum contagiosum, verruca vulgaris, actinic keratosis, basal cell carcinoma, squamous cell carcinoma, sebaceous cell carcinoma, melanoma).
 - f. Single or recurrent inflammatory lesions (e.g., recurrent chalazion or its mimics).
 - g. Facial dystonia (e.g., blepharospasm, hemifacial spasm).
 - h. Facial nerve palsy with exposure keratopathy (e.g. tarsorrhaphy, gold weights).
 - i. Complex lid and orbital trauma cases.
 - B. Technical/Surgical Skills
 1. Describe the indications for and perform more complicated and advanced "in office" examination techniques for less common but important oculoplastic and orbital abnormalities.
 2. Perform preoperative and intraoperative assessment of the eyelids and eyebrows (e.g., intraoperative adjustments).
 3. Recognize and treat more complex or difficult socket-related problems and complications (e.g., extrusion of implants, anophthalmic socket complications).
 4. Perform more complicated lid procedures (e.g., larger benign, recurrent, or multiple skin lesions).
 5. Perform more advanced lacrimal assessment (e.g., intraoperative and postoperative testing, more complex trauma to lacrimal system).
 6. Describe management of and treat lacrimal system abnormalities, including:
 - a. More complex congenital disorders (e.g., canalicular stenosis).
 - b. More complex acquired disorders and their treatment (e.g., conjunctivo-dacryocystorhinostomy with Jones tube).
 - c. Complex moderate trauma (e.g., requiring lacrimal intubation).
 7. Recognize typical and atypical features and describe the differential diagnosis, clinical features, and treatment of more complicated orbital diseases, including:
 - a. More complex orbital infections (e.g., preseptal and orbital cellulitis, mucormycosis, aspergillosis).
 - b. Congenital tumors (e.g., dermoid).
 - c. Fibro-osseous disorders and tumors (e.g., fibrous dysplasia, osteoma, chondrosarcoma, osteosarcoma, Paget's disease).
 - d. Vascular tumors (e.g., capillary hemangioma, cavernous hemangioma, hemangiopericytoma, lymphangioma, Kaposi's sarcoma).
 - e. Xanthomatous tumors (e.g., xanthelasma, juvenile xanthogranuloma).
 - f. Lacrimal gland tumors (e.g., benign mixed tumor, adenoid cystic carcinoma, malignant mixed tumor, lymphoma).
 - g. Neural tumors (e.g., optic nerve glioma/meningioma, neurofibromatosis, neuroblastoma).
 - h. Rhabdomyosarcoma.
 - i. Orbital pseudotumor.
 - j. Lymphoid lesions (e.g., lymphoid hyperplasia, lymphoma, leukemia).
 - k. Thyroid-related orbitopathy.
 - l. Metastatic tumors (e.g., from breast, lung, prostate, colon, melanoma).
 - m. Trauma (e.g., orbital fractures, traumatic optic neuropathy).
 - n. Anophthalmic socket – implant exposure, volume augmentation.
 8. Describe, recognize the indications for and complications of, and perform the eyelid procedures listed below:
 - a. Basic biopsy techniques.
 - b. Lateral tarsal strip.
 - c. Specialized lid suture procedures (e.g., Quickert sutures).
 - d. Medial spindle.
 - e. Retractor reinsertion.
 - f. Levator advancement.
 - g. Eyelid laceration/margin repair.
 - h. Tarsorrhaphy.
 - i. Lateral canthoplasty (canthotomy and cantholysis).
 - j. Blepharoplasty.
 - k. Facial nerve palsy – gold weight placement in the lid.
 - l. Simple eyelid reconstruction.
 - m. Orbital approaches and incisions (e.g., Kronlein, Caldwell-Luc, transconjunctival, transnasal).
 9. Describe, recognize the indications for and complications of, and perform basic orbital skills and procedures, including:
 - a. Anterior orbitotomy for tumor biopsy/excision.
 - b. Orbital floor fracture repair.
 10. Describe the indications for and interpret CT and MRI scans (e.g., orbital trauma, orbital lesions and tumors).
 11. Perform botulinum toxin injections (e.g., blepharospasm).
 12. Identify more advanced orbital pathology (e.g., complex orbital fractures, orbital tumors) on imaging studies (e.g., magnetic resonance imaging, computed tomography, ultrasound).
- ## XI. Pediatric Ophthalmology and Strabismus
- ### Basic Level Goals: PGY-2
- #### A. Cognitive Skills
1. Describe basic examination techniques for strabismus (e.g., ductions and versions, cover and uncover testing, alternate cover testing, prism cover testing).
 2. Describe basic visual development and visual assessment of the pediatric ophthalmology patient (e.g., central, steady, maintained fixation; illiterate E, Allen cards, Landolt C rings).

3. Describe basic anatomy and physiology of strabismus (e.g., innervation of extraocular muscles, primary actions, comitant and incomitant deviations, overaction and underaction, restrictive and paretic saccades and pursuit movements).
 4. Describe basic sensory adaptations for binocular vision (e.g., normal and anomalous retinal correspondence, suppression, horopter, Panum's area, fusion, stereopsis).
 5. Describe and recognize pseudostrabismus.
 6. Describe different etiologies of amblyopia (e.g., deprivation, ametropic, strabismic, anisometropic, organic).
 7. Describe etiologies of esotropia (e.g., congenital, comitant and incomitant, accommodative and non-accommodative, decompensated, sensory, neurogenic, myogenic, neuromuscular junction, restrictive, nystagmus blockage syndrome, spasm of the near, monofixation syndrome, consecutive).
 8. Describe etiologies of exotropia (e.g., congenital, comitant and incomitant, decompensated, sensory, neurogenic, myogenic, neuromuscular junction, restrictive, basic divergence excess, exophoria, convergence insufficiency).
 9. Describe various strabismus patterns (e.g., A or V pattern).
 10. Describe etiologies, evaluation, and management of vertical strabismus (e.g., neurogenic, myogenic, neuromuscular junction, oblique overaction or underaction, dissociated vertical deviation, restrictive).
 11. Describe non-surgical treatment of strabismus.
 12. Describe different forms of childhood nystagmus.
 13. Describe features, classification, and treatment indications for retinopathy of prematurity.
 14. Describe etiologies and types of pediatric cataract.
 15. Describe and recognize ocular findings in child abuse (e.g., retinal hemorrhages) and appropriately refer to child protective services or other authorities.
 16. Describe common hereditary or congenital ocular motility or lid syndromes (e.g., Duane's syndrome, Marcus-Gunn jaw-winking, Brown syndrome).
 17. Describe typical features of retinoblastoma.
 18. Describe basic features of dyslexia.
 19. Describe basic evaluation of decreased vision in infants and children (e.g., retinopathy of prematurity, hereditary retinal disorders, congenital glaucoma, measles, vitamin A deficiency).
 20. Describe identifiable congenital ocular anomalies (e.g., microphthalmia, persistent fetal vasculature).
 21. Describe ocular findings in inherited, metabolic disorders.
 - a. Mucopolysaccharoidoses (e.g., Hurler syndrome, Scheie syndrome, Hunter syndrome, Sanfilippo syndrome, Morquio syndrome, Sly syndrome)
 - b. Lipidoses (e.g., Tay-Sachs disease, Sandhoff, Niemann-Pick, Krabbe's, Gaucher's, Fabry's disease, metachromatic leukodystrophy)
 - c. Aminoacidurias (e.g., homocystinuria, cystinosis, Lowe and Zellweger syndromes).
 22. Describe ocular findings in chromosomal abnormalities (e.g., trisomy 21; trisomy 13; trisomy 18; deletion of the short arm of chromosome 11; deletion of the long arm of chromosome 13; Cri du Chat syndrome, Turner's syndrome).
- B. Technical/Surgical Skills**
1. Perform an extraocular muscle examination based on knowledge of the anatomy and physiology of ocular motility.
 2. Assess ocular motility using testing of ductions and versions.
 3. Apply Hering's and Sherrington's laws.
 4. Perform basic measurement of strabismus (e.g., Hirschberg test, Krinsky method, cover testing, prism cover testing, simultaneous prism cover testing, alternate cover testing, Parks-Bielschowsky three-step test, Lancaster red-green test, Maddox rod testing, double Maddox rod testing).
 5. Perform assessment of vision in the neonate, infant, and child.
 6. Recognize and apply in a clinical setting the following skills in the ocular motility examination:
 - a. Stereoacuity testing.
 - b. Accommodative convergence/accommodation ratio (e.g., heterophoria method, gradient method).
 - c. Tests of binocularity and retinal correspondence.
 - d. Cycloplegic refraction (retinoscopy).
 - e. Anterior and posterior segment examination.
 - f. Basic and advanced measurement of strabismus.
 - g. Cover test measurement.
 - h. Assessment of vision.
 - i. Teller acuity cards.
 - ii. Fixation preference test.
 - iii. Standard subjective visual acuity tests.
 - iv. Induced tropia test.
 7. Assist a primary surgeon in performing extraocular muscle surgery including:
 - a. Recession.
 - b. Resection
 - c. Muscle weakening (e.g., tenotomy) and strengthening (e.g., tuck) procedures.
 - d. Transposition.
 - e. Use of adjustable sutures.

Standard Level Goals: PGY-3

A. Cognitive Skills

1. Describe basic and more advanced strabismus examination techniques (e.g., combined vertical and horizontal prism cover testing, double Maddox rod testing).
2. Describe basic and more advanced visual development and visual assessment of the pediatric ophthalmology patient (e.g., blink to light or threat, measures of fixation and following behavior, objective measures of visual acuity).
3. Describe more advanced anatomy and physiology of strabismus (e.g., torsion, tertiary actions, consecutive deviations).
4. Describe more advanced sensory adaptations (e.g., anomalous head position).
5. Describe basics of binocular sensory testing (e.g., Titmus stereo testing, Randot stereo testing, Worth four-dot, Bagolini lenses, afterimage testing).
6. Describe and recognize different etiologies of amblyopia.
7. Describe and recognize etiologies of esotropia.
8. Describe and recognize etiologies of exotropia.

9. Describe and recognize various strabismus patterns (e.g., A or V pattern).
 10. Describe and recognize the etiologies of vertical strabismus.
 11. Describe and utilize the non-surgical treatment of strabismus and amblyopia (e.g., patching, atropine penalization, Fresnel and grind-in prism therapy).
 12. Describe and recognize the different forms of childhood nystagmus (e.g., sensory, motor, congenital, acquired).
 13. Describe and recognize retinopathy of prematurity (e.g., stages, treatment indications).
 14. Describe and recognize etiologies and types of pediatric cataract (e.g., congenital, traumatic, hereditary, idiopathic).
 15. Describe and recognize less common hereditary or malformative ocular anomalies and syndromes (e.g., Mobius, Goldenhar syndrome).
 16. Describe and recognize typical features of retinoblastoma (e.g., differential diagnosis, evaluation, treatment indications and types).
 17. Describe the main features of dyslexia and its relationship to vision.
 18. Describe basic evaluation and differential diagnosis of decreased vision in infants and children (e.g., retinal and optic nerve etiologies, amblyopia).
 19. Describe recognizable causes of blindness in infants (e.g., albinism, optic nerve hypoplasia, achromatopsia, Leber's congenital amaurosis, retinal dystrophy, congenital optic atrophy).
 20. Describe etiology, evaluation, and management of congenital infections (e.g., toxoplasmosis, rubella, cytomegalovirus, syphilis, herpes).
 21. Describe and recognize the common causes of pediatric uveitis.
- B. Technical Skills**
1. Perform a more advanced extraocular muscle examination based on knowledge of the anatomy and physiology of ocular motility.
 2. Assess more advanced ocular motility problems (e.g., bilateral or multiple cranial neuropathy, myasthenia gravis, thyroid eye disease).
 3. Apply Hering's and Sherrington's laws in more advanced cases (e.g., pseudoparesis of the contralateral antagonist, enhancement of ptosis in myasthenia gravis).
 4. Perform more advanced measurements of strabismus (e.g., double Maddox rod testing, Lancaster red green testing, use of synoptophore or amblyoscope).
 5. Perform assessment of vision in more difficult strabismus patients (e.g., uncooperative child, mentally impaired, nonverbal or preverbal).
 6. Perform basic extraocular muscle surgery:
 - a. Exercise surgical judgement for the indications and contraindications for strabismus surgery.
 - b. Perform preoperative assessment, intraoperative techniques, and describe intraoperative and postoperative complications of strabismus surgery.
 - c. Perform the following strabismus surgeries:
 - i. Recession.
 - ii. Resection.
 - iii. Muscle weakening (e.g., tenotomy) and strengthening (e.g., tuck) procedures.

- iv. Transposition.
 - v. Use of adjustable sutures.
- d. Manage the complications of strabismus surgery (e.g., slipped muscle, anterior segment ischemia).

Advanced Level Goals: PGY-4

A. Cognitive Skills

1. Describe and perform the most advanced strabismus examination techniques (e.g., complicated prism cover testing in multiple cranial neuropathies, patients with nystagmus, dissociated vertical deviation, double Maddox rod testing).
2. Perform the most advanced techniques for assessment of visual development in complicated or non-cooperative pediatric ophthalmology patients (e.g., less common objective measures of visual acuity, electrophysiologic testing).
3. Apply the most advanced knowledge of strabismus anatomy and physiology (e.g., spiral of Tillaux, secondary and tertiary actions, spread of comitance) in evaluation of patients.
4. Describe clinical application of the most advanced sensory adaptations (e.g., anomalous head position, anomalous retinal correspondence).
5. Recognize and treat the most complicated etiologies of amblyopia (e.g., refraction non-compliance, patching failures, pharmacologic penalization).
6. Recognize and treat the most complex etiologies of esotropia (e.g., optical, prism-induced, postsurgical/consecutive).
7. Recognize and treat the most complex etiologies of exotropia (e.g., supranuclear, paralytic pontine exotropia, consecutive).
8. Recognize and treat the most complex strabismus patterns (e.g., aberrant regeneration, postsurgical, thyroid ophthalmopathy, and myasthenia gravis).
9. Recognize and treat the most complex etiologies of vertical strabismus (e.g., skew deviation, postsurgical, restrictive).
10. Apply non-surgical treatment (e.g., patching, atropine penalization) of more complicated forms of amblyopia (e.g., non-compliant, patching failures).
11. Recognize, evaluate, and treat the most complex forms of childhood nystagmus (e.g., sensory, spasmus nutans, associated with neurologic or systemic diseases).
12. Recognize and treat (or refer for treatment) complex retinopathy of prematurity (e.g., stages, treatment indications, retinal detachment).
13. Recognize and treat (or refer for treatment) uncommon etiologies and types of pediatric cataract (e.g., congenital, traumatic, metabolic, inherited).
14. Recognize and appropriately evaluate the more complex hereditary ocular syndromes (e.g., bilateral Duane syndrome, Mobius syndrome).
15. Recognize and treat (or refer for treatment) patients with complicated retinoblastoma (e.g., bilateral cases, monocular patient, treatment failure, pineal involvement).
16. Recognize and evaluate the less common congenital ocular anomalies (e.g., unusual genetic syndromes).
17. Apply the most advanced principles of binocular vision and amblyopia (e.g., physiology of binocular vision, di-

lopia, confusion and suppression, normal and abnormal retinal correspondence, classification and characteristics of amblyopia).

18. Recognize and treat complex pediatric retinal diseases (e.g., inherited retinopathies).
 19. Recognize and treat complex pediatric glaucoma.
 20. Recognize and treat complex pediatric cataract and anterior segment abnormalities (including surgical implications, techniques, and complications).
 21. Recognize and treat complex pediatric eyelid disorders (e.g., congenital deformities, lid lacerations, lid tumors).
 22. Recognize and treat (or refer) pediatric orbital diseases (e.g., orbital tumors, orbital fractures, rhabdomyosarcoma, severe congenital orbital malformations).
- B. Technical/Surgical Skills**
1. Perform more complex extraocular muscle surgery (e.g., vertical and horizontal muscle surgery; reoperations).
 2. Describe indications and contraindications for more complex strabismus surgery.
 3. Describe and perform the preoperative assessment, intraoperative techniques and describe postoperative complications for more complicated strabismus surgery (e.g., reoperations, slipped muscle).
 4. Describe indications for and perform adjustable sutures in more complicated cases (e.g., thyroid ophthalmopathy).
 5. Describe and manage more complex complications of strabismus surgery (e.g., globe perforation, endophthalmitis, overcorrection).

XII. Vitreoretinal Diseases



Basic Level Goals: PGY-2

- A. Cognitive Skills**
1. Describe basic principles of retinal anatomy and physiology (layers of the retina, retinal physiology).
 2. Describe fundamentals and demonstrate basic understanding of fluorescein angiography as applied to retinal vascular diseases (e.g., indications, phases of the angiogram).
 3. Describe etiologies and mechanisms of retinal detachment.
 4. Describe macular anatomy and function and describe typical features of common macular diseases (e.g., age-related macular degeneration, macular hole, macular dystrophies, macular pucker).
 5. Describe basic principles of laser photocoagulation.
 6. Describe and recognize features of commotio retinae, traumatic choroidal rupture, and Purtscher's retinopathy.
 7. Describe common forms of retinal vascular diseases (e.g., branch, hemi- or central retinal vein and artery occlusion).
 8. Describe typical features of retinitis pigmentosa.
 9. Describe features of, recognize, and evaluate posterior vitreous detachments and retinal detachments.
- B. Technical/Surgical Skills**
1. Perform direct ophthalmoscopy.
 2. Perform indirect ophthalmoscopy.
 3. Perform slit lamp biomicroscopy with the Hruby, +78, +90 lenses, 3-mirror contact lens, or other contact lenses (e.g., TransEquator).

4. Interpret basic fluorescein angiography in common retinal disorders (e.g., diabetic retinopathy, cystoid macular edema).

Standard Level Goals: PGY-3

- A. Cognitive Skills**
1. Describe more advanced retinal anatomy and physiology.
 2. Describe more advanced concepts of fluorescein/indocyanine green (ICG) angiography as applied to retinal vascular and other diseases (e.g., indications, phases of the angiogram).
 3. Describe principles of retinal detachment recognition, various types of retinal detachment (e.g., exudative, rhegmatogenous, tractional), and their evaluation, management, and repair (e.g., identify retinal break).
 4. Describe and recognize typical features of less common macular diseases (e.g., parafoveal telangiectasias, cone dystrophies, inherited macular dystrophies, fundus flavimaculatus, toxic maculopathies).
 5. Describe indications for and complications of laser photocoagulation.
 6. Describe the findings of major studies in retinal diseases, including the following:
 - a. Diabetic Retinopathy Study (DRS).
 - b. Diabetic Vitrectomy Study (DVS).
 - c. Early Treatment of Diabetic Retinopathy Study (ETDRS).
 - d. Macular Photocoagulation Study (MPS).
 - e. Diabetes Control and Complications Trial (DCCT).
 - f. Branch Vein Occlusion Study (BVOS).
 - g. Central Vein Occlusion Study (CVOS).
 - h. United Kingdom Prospective Diabetes Study (UKPDS).
 - i. Age-Related Eye Disease Study (AREDS).
 - j. Verteporfin in Photodynamic Therapy Study (VIP).
 - k. Treatment of Age-Related Macular Degeneration with Photodynamic Therapy Study (TAP).
 7. Describe the fundamentals of, evaluate, and treat (or refer) peripheral retinal diseases and vitreous pathology (e.g., vitreous hemorrhage, retinal breaks).
 8. Describe, evaluate, and treat choroidal detachments, uveal effusion syndrome.
 9. Identify and evaluate retinoschisis (e.g., juvenile, senile).
 10. Diagnose, treat, and recognize the complications of retinopathy of prematurity (e.g., retinal detachment).
 11. Diagnose, evaluate, and treat the following retinal vascular diseases:
 - a. Arterial and venous obstructions.
 - b. Diabetic retinopathy.
 - c. Hypertensive retinopathy.
 - d. Peripheral retinal vascular occlusive disease.
 - e. Acquired retinal vascular diseases.
 - f. Ocular ischemic syndrome.
 - g. Sick cell retinopathy.
 - h. Retinal pigment epithelial detachment.
 12. Describe and recognize common and uncommon macular disorders:
 - a. Age-related macular degeneration (ARMD).
 - b. Choroidal neovascularization (e.g., ARMD, histoplasmosis).
 - c. High myopia.
 - d. Macular dystrophies.

- e. Macular pucker (e.g., epiretinal membrane).
 - f. Macular holes.
 - g. Cystoid macular edema.
 - h. Central serous choroidopathy (retinopathy).
 - i. Optic pit and secondary serous detachment.
 - j. Retinal pigment epithelial detachment.
 13. Describe the fundamentals of retinal electrophysiology.
 14. Describe, recognize, and evaluate hereditary retinal and choroidal diseases (e.g., gyrate atrophy, choroideremia, retinitis pigmentosa, cone dystrophies, Stargardt's disease, Best's disease, congenital stationary night blindness).
 15. Recognize, evaluate, and treat (or refer) retinal and choroidal toxicity (e.g., phenothiazine, hydroxychloroquine/chloroquine toxicity, tamoxifen).
 16. Describe the techniques for retinal detachment repair (e.g., pneumatic retinopexy, scleral buckling, vitrectomy).
 17. Describe the basics of surgical vitrectomy (e.g., indications, mechanics, instruments, and technique).
 18. Describe the indications for and perform basic laser treatment for diabetic retinopathy (e.g., panretinal photocoagulation, macular grid).
 19. Describe the fundamentals of special vitreoretinal techniques:
 - a. Macular hole repair.
 - b. Epiretinal membrane peeling.
 - c. Complex vitrectomy for proliferative vitreoretinopathy.
 - d. Use of heavy liquids and intraocular gases (e.g., perfluorocarbons).
 20. Describe, evaluate, and treat posterior uveitis syndromes and endophthalmitis.
- B. Technical/Surgical Skills**
1. Perform indirect ophthalmoscopy with scleral indentation.
 2. Perform ophthalmoscopic examination with contact lenses, including panfunduscopy lenses.
 3. Interpret fluorescein and ICG angiography.
 4. Describe the indications for and interpret retinal imaging technology (e.g., ocular coherence tomography, retinal thickness analysis).
 5. Perform posterior segment photocoagulation.
 6. Perform diabetic focal/grid macular laser treatment.
 7. Perform peripheral scatter photocoagulation (panretinal).
 8. Perform laser retinopexy (demarcation) for isolated retinal breaks.
 9. Describe the indications for and interpret basic electrophysiological tests (e.g., electroretinogram [ERG], electrooculogram [EOG], visual evoked potential (VEP), dark adaptation).
 10. Interpret basic ocular imaging techniques (e.g., B-scan echography, nerve fiber layer analysis).
 11. Perform fundus drawings of the retina, showing complex vitreoretinal relationships and findings.
 12. Perform cryotherapy of retinal holes and other pathology.
 13. Perform scleral buckling.
 14. Describe indications, techniques, and complications of pars plana vitrectomy and assist in a retinal surgery or perform the procedure under supervision.

Advanced Level Goals: PGY-4

A. Cognitive Skills

1. Apply in clinical practice the most advanced knowledge of retinal anatomy and physiology (e.g., surgical anatomy).
2. Apply in clinical practice the most advanced concepts of fluorescein/ICG angiography in complex retinal vascular and other diseases (e.g., occult choroidal neovascular membranes, recurrent neovascularization, vascular tumors, diseases of choroid and retinal pigment epithelium).
3. Evaluate, treat, or refer the most complex retinal detachments (e.g., recurrent retinal detachment, proliferative vitreoretinopathy).
4. Evaluate, treat or refer the most complex macular disease (e.g., subfoveal or recurrent neovascular membranes).
5. Describe the indications for laser photocoagulation, including photodynamic therapy for the most complex retinal pathology (e.g., subfoveal neovascular membranes).
6. Describe the findings of the major studies in retinal diseases and describe the indications and exceptions for application to individual patients:
 - a. Diabetic Retinopathy Study (DRS).
 - b. Diabetic Vitrectomy Study (DVS).
 - c. Early Treatment of Diabetic Retinopathy Study (ETDRS).
 - d. Macular Photocoagulation Study (MPS).
 - e. Diabetes Control and Complications Trial (DCCT).
 - f. Branch Vein Occlusion Study (BVOS).
 - g. Central Vein Occlusion Study (CVOS).
 - h. United Kingdom Prospective Diabetes Study (UKPDS).
 - i. Treatment of Age-related Macular Degeneration with Photodynamic Therapy (TAP; VIP).
7. Apply in clinical practice understanding of the most complex peripheral retinal diseases and vitreous pathology (e.g., Goldmann-Favre disease, incontinentia pigmenti, familial exudative vitreoretinopathy).
8. Evaluate and treat complications of retinal photocoagulation (e.g., vitreous hemorrhage, chorioretinal anastomoses).
9. Recognize and treat complex retinal detachments (e.g., giant tear).
10. Evaluate, treat or refer the more complex cases of retinopathy of prematurity (e.g., tractional retinal detachment).
11. Evaluate, treat, or refer the most complex forms of retinal vascular diseases:
 - a. Combined arterial and venous obstructions.
 - b. Advanced diabetic retinopathy.
 - c. Advanced hypertensive retinopathy.
 - d. Peripheral retinal vascular occlusive disease.
 - e. Acquired retinal vascular diseases.
12. Evaluate and treat or refer the uncommon manifestations or presentations of the following macular diseases:
 - a. Age-related macular degeneration (ARMD)/choroidal neovascularization (e.g., recurrent subfoveal neovascularization).
 - b. Uncommon macular dystrophies.
 - c. Refractory cystoid macular edema.
 - d. Recurrent central serous choroidopathy (retinopathy).
 - e. Acute posterior multifocal placoid pigment epitheliopathy (choroidopathy).

- f. Multiple evanescent white dot syndromes.
- g. Serpiginous choroiditis.
- h. Acute zonal outer retinopathy.
- i. Triangular syndrome.
- j. Polypoidal choroidopathy.
- 13. Apply in clinical practice the more complex retinal electrophysiology (e.g., multifocal electroretinography).
- 14. Apply in clinical practice the more complex techniques for retinal detachment repair:
 - a. Repeat scleral buckling.
 - b. Pars plana vitrectomy (e.g., diagnostic tap; core vitrectomy, extensive vitrectomy).
 - c. Repair of uveal effusion.
- 15. Apply in clinical practice the more complex principles of surgical management of diabetic retinopathy (e.g., vitrectomy, membrane release).
- 16. Apply in clinical practice complex vitreoretinal techniques:
 - a. Macular hole repair.
 - b. Epiretinal membrane peeling.
 - c. Complex vitrectomy for proliferative vitreoretinopathy.
 - d. Use of heavy liquids.
- 17. Evaluate, treat, or refer the etiologically more complex or uncommon cases of posterior uveitis (e.g., sympathetic ophthalmia) and endophthalmitis (e.g., endogenous).
- B. Technical/Surgical Skills
 - 1. Perform indirect ophthalmoscopy with scleral indentation in complex retinal cases (e.g., multiple holes, documented with detailed retinal drawing).
 - 2. Perform ophthalmoscopic examination with panfunduscopy or other lenses in complex retinal conditions (e.g., giant retinal tears, proliferative vitreoretinopathy).
 - 3. Interpret and apply in clinical practice the results of fluorescein and ICG angiography and optical coherence tomography (OCT) in complex retinal or choroidal pathology (e.g., occult subretinal neovascular membrane).
 - 4. Perform posterior segment photocoagulation in more complicated retinal cases:
 - a. Diabetic focal/grid macular treatment (e.g., monocular patient, repeat treatment).
 - b. Repeat peripheral scatter photocoagulation (panretinal).
 - c. Laser retinopexy (demarcation) of large or multiple breaks; cryotherapy.
 - 5. Interpret and apply in clinical practice electrophysiology (e.g., ERG, EOG, VEP, dark adaptation) in more complicated retinal pathology.
 - 6. Interpret and apply in clinical practice ocular imaging techniques (e.g., B-scan echography) in more complex cases (e.g., choroidal osteoma).
 - 7. Perform detailed fundus drawings of the retina with vitreoretinal relationships in the most complex retinal cases (e.g., recurrent retinal detachment, retinoschisis with and without retinal detachment).
 - 8. Perform laser therapy or cryotherapy of retinal holes and other more complex retinal pathology.
 - 9. Perform scleral buckling in complex retinal detachment.
 - 10. Perform advanced pars plana vitrectomy.

XIII. Uveitis



Basic Level Goals: PGY-2

A. Cognitive Skills

1. Describe basic principles of history taking and examination of patients with uveitis, and related diseases (e.g., scleritis, pemphigus).
2. List signs and symptoms of anterior and posterior uveitis (e.g., red eye, blurred vision, anterior segment cell and flare, vitreous opacities, pars planitis, retinal or choroidal infiltrates).
3. Describe the different types of uveitis (e.g., acute and chronic uveitis, granulomatous and non-granulomatous uveitis, anterior, intermediate, and posterior uveitis).
4. Describe typical features and differential diagnosis of anterior uveitis, including infectious (e.g., bacterial, viral, protozoal, parasite), inflammatory (e.g., sarcoid, HLA-B27-associated, Behcet's disease, collagen vascular disease), neoplastic (masquerade syndromes), postsurgical, post-traumatic, Fuchs' heterochromic uveitis, juvenile rheumatoid arthritis.
5. Describe typical features and differential diagnosis of the following posterior segment uveitis.
 - a. Toxoplasmosis.
 - b. Sarcoidosis.
 - c. Pars planitis.
 - d. Acute retinal necrosis.
 - e. Vogt-Koyanagi-Harada syndrome.
 - f. Large cell lymphoma.
 - g. Postoperative uveitis.
 - h. Endophthalmitis (e.g., postoperative, traumatic, endogenous, fungal, phacoanaphylactic, sympathetic ophthalmia).
 - i. Unusual infectious etiologies for uveitis (e.g., human immunodeficiency virus, herpes simplex virus, herpes zoster virus, pneumocystis carinii, Lyme disease).
 - j. Acquired and congenital ocular syphilis.
 - k. Cytomegalovirus retinitis.
 - l. Multiple sclerosis.

B. Technical/Surgical Skills

1. Perform an examination of the anterior and posterior segment for uveitis (e.g., slit lamp biomicroscopy, scleral depression, magnified posterior segment exam, vitreous evaluation for cells, retinal, choroidal, and pars plana evaluations).
2. Describe indications for ancillary testing in the evaluation of uveitis (e.g., fluorescein angiography, ultrasound, laboratory testing, radiologic testing).

Standard Level Goals: PGY-3

A. Cognitive Skills

1. Describe more advanced principles of history taking and examination of patients with uveitis (e.g., review of systems for Wegener's granulomatosis, polyarteritis nodosa, lupus erythematosus, rheumatoid arthritis, inflammatory bowel disease, systemic necrotizing vasculitis; evaluation of skin, cardiac, respiratory, renal, pulmonary, musculoskeletal systems).
2. List less common signs and symptoms of anterior and posterior uveitis.

3. List differentiating signs of less common forms of uveitis (e.g., iris nodules, conjunctival ulcer or granuloma).
4. Describe the differential diagnosis of less common forms of uveitis (e.g., chronic uveitis, intermediate uveitis [e.g., pars planitis], and infectious [e.g., Whipple disease, syphilis] or inflammatory posterior uveitis; masquerade syndromes, including large cell lymphoma).
5. Evaluate and treat common causes of anterior and posterior uveitis.

B. Technical/Surgical Skills

1. Perform a directed examination of the anterior and posterior segments for uveitis (e.g., slit lamp biomicroscopy, scleral depression, magnified posterior segment exam, vitreous evaluation for cells).
2. Perform ancillary testing in the evaluation of uveitis (e.g., fluorescein angiography, ultrasound, laboratory testing, radiologic testing).

Advanced Level Goals: PGY-4

A. Cognitive Skills

1. Recognize, evaluate and treat uveitis associated with immunosuppressed individuals (e.g., active and recovered acquired immune deficiency syndrome, pharmacologic immunosuppression).
2. Recognize, evaluate, and treat acquired and congenital ocular syphilis.
3. Recognize, evaluate, and treat (or refer) less common, rare, or tropical conditions associated with uveitis (e.g., Leishmaniasis).
4. Describe indications and contraindications for corticosteroid treatment of uveitis (e.g., topical, local, systemic), including risks and benefits of therapy.
5. Describe indications and contraindications for immunosuppressive therapy in uveitis, use of antimetabolites, cyclosporine, alkylating agents.

B. Technical/Surgical Skills

1. Administer steroids in the treatment of uveitis by various routes.
2. Administer immunosuppressive agents in uveitis (or refer for administration).
3. Evaluate and treat the complications of uveitis therapy (e.g., cataract, glaucoma).
4. Biopsy, when indicated, the vitreous or uveal tract.
5. Insert intravitreal implants containing antiviral or corticosteroid medications.
6. Perform, when indicated, vitrectomy or scleral buckling procedures.

XIV. Ocular Oncology



Basic Level Goals: PGY-2

A. Cognitive Skills

1. Describe the basic categorization of common extraocular and intraocular tumors.
2. Describe the differential diagnosis, epidemiology, evaluation, and management of leukocoria (e.g., inflammatory, infectious, neoplastic, congenital, persistent fetal vasculature, cataract, Coats' disease, vitreous hemorrhage, retinal detachment).

3. Describe major diagnostic features of major intraocular tumor types (e.g., retinoblastoma, choroidal melanoma, metastatic lesions) and describe the differentiating features of similar lesions.

B. Technical/Surgical Skills

1. Perform slit lamp, ophthalmoscopic and ocular transillumination examination of patients with intraocular tumors (e.g., choroidal melanoma).
2. Recognize an ocular tumor and refer appropriately.

Standard Level Goals: PGY-3

A. Cognitive Skills

1. Describe management options for different intraocular tumors.
2. Describe the findings of the Collaborative Ocular Melanoma Study (COMS).
3. Describe the classification of retinoblastoma and its treatment.
4. Describe basic histopathology of intraocular tumors.
5. List the differential diagnoses for tumors of the iris, ciliary body, choroid, retina and optic disc (e.g., melanoma, retinoblastoma, hemangioma, melanocytoma).
6. Describe diagnostic techniques for common intraocular tumors (e.g., physical examination, imaging, laboratory, oncology referral).
7. Describe the prognostic significance of different types of ocular tumors and be able to guide evaluation for systemic involvement.

B. Technical/Surgical Skills

1. Perform indirect ophthalmoscopy in the diagnosis and localization of intraocular tumors.
2. Perform transillumination for intraocular tumor.
3. Describe indications for an examination under anesthesia for pediatric intraocular tumors.
4. Describe indications for A-scan and B-scan echography of intraocular mass lesions.
5. Describe indications for fluorescein angiography of intraocular tumors.
6. Describe indications for destruction or excision of conjunctival, corneal, and intraocular tumors.
7. Describe indications for laser photocoagulation for intraocular tumors.
8. Describe indications for and techniques of transpupillary thermal therapy for intraocular tumors.
9. Recognize major histopathologic appearance of common intraocular tumors.
10. Describe the indications for surgical or other therapeutic procedures and their complications, and for referral, if necessary, for:
 - a. Plaque or other radiotherapy.
 - b. Iridectomy and iridocyclectomy.
 - c. Resection of conjunctival tumors.
11. Perform an enucleation.
12. Describe indications for and techniques and complications of radiation therapy for ocular tumors (e.g., radioactive plaque localization, external beam radiation, radiation retinopathy).
13. Discuss various treatment options with patients and their families in a detailed, ethical, and compassionate manner.

Advanced Level Goals: PGY-4**A. Cognitive Skills**

1. Describe management options for unusual intraocular tumors (e.g., choroidal metastasis, choroidal osteoma).
2. Apply the findings of the Collaborative Ocular Melanoma Study (COMS).
3. Recognize, evaluate, and treat most forms of extraocular and intraocular tumors.

B. Technical/Surgical Skills

1. Perform indirect ophthalmoscopy for the diagnosis and localization of intraocular tumors prior to treatment.
2. Describe indications for and perform an examination under anesthesia for pediatric intraocular tumors (e.g., retinoblastoma).
3. Describe indications for and interpret A-scan and B-scan echography of intraocular mass lesions.
4. Describe indications for and interpret fluorescein angiography of intraocular tumors.
5. Describe indications for and perform excision or other treatment of conjunctival, corneal, and intraocular tumors.
6. Describe indications for and perform laser photocoagulation for intraocular tumors.
7. Recognize major histopathologic appearance of common and less common intraocular tumors.
8. Describe indications for surgical procedures and their complications and be able to perform or refer for:
 - a. Plaque radiotherapy.
 - b. External beam radiotherapy.
 - c. Iridectomy and iridocyclectomy.
 - d. Resection or cryotherapy of conjunctival tumors, or use of antimetabolite eyedrops.
 - e. Transpupillary thermal therapy.
9. Perform a complicated enucleation (e.g., complicated by hemorrhaging, small orbit, scar tissue) or exenteration.

XV. Low Vision Rehabilitation**Basic Level Goals: PGY-2****A. Cognitive Skills**

1. Describe low vision assessment techniques (e.g., Early Treatment of Diabetic Retinopathy Study charts, Sloane charts).
2. Describe significant co-morbidities that impact low vision rehabilitation.
3. Describe various low vision aids.
4. Describe the optics of low vision devices.
5. Be sensitive to psychological and emotional aspects of visual impairment.
6. Describe challenges commonly encountered by individuals with visual impairments.
7. Prescribe simple but appropriate rehabilitative therapies and optical devices to help the patient meet their goals. (e.g., magnification, illumination).
8. Describe functional implications of various visual system pathologies and diseases.
9. Describe visual field enhancing techniques for hemianopic field loss.
10. Describe the difference between visual acuity testing at both distance and near and contrast sensitivity testing.

11. Describe the evaluation of and rationale for licensing automobile drivers who are visually impaired; understand the local licensing regulations.
12. Describe evaluation of visual acuity and visual field for determination of disability.

Standard Level Goals: PGY-3**A. Cognitive Skills**

1. Recognize significant co-morbidities that impact low vision rehabilitation.
2. Recognize and describe clinical applications, indications, and limitations of the various low vision aids (e.g., closed circuit television, magnification, large print, Braille, computers with artificial speech).
3. Describe the more advanced optics of low vision devices.

B. Technical/Surgical Skills

1. Prescribe more complex rehabilitative therapies and optical devices to help the patient meet their goals.
2. Apply and prescribe visual field enhancing techniques for hemianopic field loss.
3. Perform evaluation of vision assessment in licensing drivers who are visually impaired.
4. Evaluate visual acuity and visual field for determination of disability (for legal and insurance purposes).
5. Demonstrate low vision devices and educate low vision patients on the uses and limitations of these devices.

Advanced Level Goals: PGY-4**A. Cognitive Skills**

1. Treat significant co-morbidities that impact low vision rehabilitation.
2. Describe indications for the most complex low vision aids.
3. Apply more complex principles of optics of low vision devices.

B. Technical/Surgical Skills

1. Prescribe the most complex rehabilitative therapies and optical devices to help the patient meet their goals.
2. Apply and prescribe the most complex visual field enhancing techniques for hemianopic field loss.

XVI. Ophthalmic Practice and Ethics

(Some of the goals listed here are applicable only to selected countries, e.g., USA, UK, and Canada)

Basic Level goals: Pgy-2

1. Describe the fundamentals and principles of medical ethics in ophthalmology (e.g., patient care decision-making, informed consent, competency issues, ethics of inter-collegial relations, risk management, privacy issues).
2. Describe the basics of ophthalmic practice management (e.g., contractual negotiations, hiring and supervising employees, financial management, working with associates, billing/collecting).
3. Describe the basics of the health care system and reimbursement, as appropriate to the local, regional, and national market of the trainee (e.g., third party payers, managed care,

Medicare (USA), medical documentation, Medicaid (USA), private insurance, nationalized health care systems (UK, Canada, and others).

Standard Level Goals: PGY-3

1. Describe and apply more advanced principles of medical ethics (e.g., life and death patient care decision-making, ethics of optometric and non-physician relations, documentation requirements, insurance claims, and risk management).
2. Describe and apply more advanced aspects of practice management (e.g., business models, documentation requirements and coding, privacy requirements, dealing with patients or employees with disabilities).
3. Describe and apply more advanced aspects of health care reimbursement (e.g., physicians' role in managed care organizations, administrative role, third party reimbursement, capitated programs).

Advanced Level Goals: PGY-4

1. Demonstrate proficiency in more advanced principles of medical ethics (e.g., informed consent in children, the mentally ill, disabled, or the demented patient; physician and industry relationships; acceptance and disclosure of gifts or consultation fees).
2. Utilize in clinical practice the principles of practice management (e.g., starting a practice, economics of starting a practice, licensing and credentialing applications).
3. Utilize in clinical practice more advanced aspects of health care reimbursement (e.g., denials of claims, hospital contracting, electronic billing).

XVII. General References



1. Congdon NG, Friedman DS, Lietman T. Important causes of visual impairment in the world today. *Jama* 2003; 290: 2057–2060
2. Liesegang TJ, Hoskins HD Jr., Albert DM et al. Ophthalmic education: where have we come from, and where are we going? *Am J Ophthalmol* 2003; 136: 114–121
3. Okada AA. International guidelines: all for one and one for all? *Arch Ophthalmol* 2003; 121: 1043–1044
4. Lee AG. Using the American Journal of Ophthalmology's website for assessing residency subcompetencies in practice-based learning. *Am J Ophthalmol* 2004; 137: 206–207
5. Lee AG. The new competencies and their impact on resident training in ophthalmology. *Surv Ophthalmol* 2003; 48: 651–662
6. The "Atlas of Ophthalmology" (www.atlasophthalmology.com) is an online multimedia database edited by Georg Michelson, MD, from the University Augenklinik in Erlangen, Germany and Robert Machemer, MD, from Duke University in Durham, North Carolina, USA. It is endorsed by the ICO.

Useful Organization Websites

1. American Academy of Ophthalmology: <http://www.aao.org> and the AAO's Education Resource Center: <http://www.aao.org/education/index.cfm>

2. American Board of Ophthalmology: <http://www.abop.org>
3. Digital Journal of Ophthalmology: <http://www.djo.harvard.edu>
4. Eye Search: <http://www.eyesearch.com>
5. EyeAtlas – Online Atlas of Ophthalmology: <http://www.eyeatlas.com>
6. Eye Cancer Network: <http://eyecancer.com>
7. Eye Library.Org: <http://www.eyelibrary.org>
8. Eye Text.Net: <http://www.eyetext.net>
9. Accreditation Council for Graduate Medical Education: <http://www.acgme.org>
10. Images of eye diseases: <http://www.redatlas.org>
11. International Council of Ophthalmology: <http://www.icoph.org> (has links for Basic and Clinical Assessments, i.e., testing and examinations; email address: assess@icoph.org)
12. Ophthalmic resource searches (i.e., search for "eye resources on the Internet" or search by ophthalmic keywords): <http://www.google.com>
13. New York Eye & Ear Infirmary: Digital Atlas of Ophthalmology http://www.nyee.edu/page_deliv.html?page_no=50
14. Royal College of Ophthalmologists: <http://www.rcophth.ac.uk>
15. Royal Australian and New Zealand College of Ophthalmology: <http://www.ranzco.edu>
16. Wilmer Ophthalmological Institute: <http://www.wilmereyeinstitute.net>

Selected Ophthalmology Journal Websites

1. Acta Ophthalmologica Scandinavica: <http://www.blackwellpublishing.com/journals/aos>
2. American Journal of Ophthalmology: <http://www.ajo.com>
3. Ophthalmology: <http://www.aao.org>
4. Several sub-specialty journals are available through: <http://www.ophsources.org>
5. Archives of Ophthalmology: <http://www.archophthalmol.com>
6. British Journal of Ophthalmology: www.bjophthalmol.com
7. Canadian Journal of Ophthalmology: <http://www.eyesite.ca>
8. Clinical and Experimental Ophthalmology: <http://www.blackwellpublishing.com/journals/aos>
9. Current Opinion in Ophthalmology: <http://www.co-ophthalmology.com>
10. European Journal of Ophthalmology: <http://www.eur-j-ophthalmol.com/ejo/>
11. Eye: <http://www.nature.com/eye/>
12. Graefe's Archive for Clinical and Experimental Ophthalmology: <http://www.springerlink.com>
13. International Ophthalmology Clinics: <http://www.internat-ophthalmology.com>
14. Investigative Ophthalmology and Visual Science: <http://www.iovs.org>
15. Japanese Journal of Ophthalmology: <http://www.springerlink.com>
16. Ophthalmologica: <http://www.karger.com>
17. Transactions of the American Ophthalmological Society: <http://www.aosonline.org>
18. Lippincott Williams and Wilkins: <http://www.lwwonline.com>

XVIII. Literature and Studies for Review



General References (Books)

1. Albert DM, Jakobiec FA. Principles and practice of ophthalmology. 2nd ed. Philadelphia: W.B. Saunders Co.; 2000
2. Duke-Elder S. System of ophthalmology. St. Louis: Mosby; 1941–1972
3. Easty DL, Sparrow JM. Oxford textbook of ophthalmology, 2v. Oxford ; New York: Oxford University Press; 1999
4. Forrester JV. The eye: Basic sciences in practice. 2nd ed. Edinburgh ; New York: W.B. Saunders; 2002
5. Galloway NR. Common eye diseases and their management. 2nd ed. London: Springer; 1999
6. Gold DH, Weingeist TA. The eye in systemic disease. Philadelphia: J.B. Lippincott; 1990
7. Gold DH, Weingeist TA. Color atlas of the eye in systemic disease. Philadelphia: Lippincott Williams & Wilkins; 2001
8. Kanski JJ. Clinical ophthalmology: a systematic approach. 4th ed. Oxford; Boston: Butterworth-Heinemann; 1999
9. Kanski JJ, Nischal KK, Milewski SA. Ophthalmology: clinical signs and differential diagnosis. London; Philadelphia: Mosby; 1999
10. Kanski JJ, Bolton A. Illustrated tutorials in clinical ophthalmology. Oxford; Boston: Butterworth-Heinemann; 2001 with accompanying CD-ROM.
11. Kuhn F, Pieramici DJ. Ocular trauma: principles and practice. New York; Stuttgart: Thieme; 2002
12. Li F. Yan ke quan shu (System of ophthalmology). Beijing: Ren min wei sheng chu ban she; 1996. (Chinese, 3 v).
13. MacCumber MW, Paton D. Management of ocular injuries and emergencies. Philadelphia: Lippincott-Raven; 1998
14. Milder B, Rubin ML. The fine art of prescribing glasses without making a spectacle of yourself. 2nd ed. Gainesville: Triad Publishing Co.; 1991
15. Rhee DJ, Pyfer MF. The Wills Eye Manual: Office and emergency room diagnosis and treatment of eye disease. 3rd ed. Philadelphia: Lippincott Williams & Wilkins; 1999
16. Spalton DJ. Atlas oftalmologia clinica. Madrid: Mosby/Doyma Libros; 1995. (Spanish translation of Spalton's 2nd edition).
17. Varma R. Essentials of eye care. The Johns Hopkins Wilmer handbook. Philadelphia: Lippincott-Raven; 1997
18. Wilson FM, Blomquist PH. Practical ophthalmology: A manual for beginning residents. 5th ed. San Francisco: American Academy of Ophthalmology; 2005
19. Yun Tong-ho, Yi Sang-uk, Ch'oe Ok. Angwahak (Ophthalmology). 6th ed. Seoul: Ilchogak; 2002. (Korean).

CORNEA

Herpetic Eye Disease Study (HEDS)

Recommended Reading

- ▶ (No authors listed). Acyclovir for the prevention of recurrent herpes simplex virus eye disease. Herpetic Eye Disease Study Group. N Engl J Med 1998; 339: 300–306
- ▶ (No authors listed). A controlled trial of oral acyclovir for the prevention of stromal keratitis or iritis in patients with herpes simplex virus epithelial keratitis. The Epithelial Keratitis Trial. The Herpetic Eye Disease Study Group. Arch Ophthalmol 1997; 115: 703–712 [erratum appears in Arch Ophthalmol 1997; 115: 1196].

- ▶ epithelial keratitis and stromal keratitis. Herpetic Eye Disease Study Group. Arch Ophthalmol 2000; 118: 1030–1036

Additional Background Reading

- ▶ (No authors listed). A controlled trial of oral acyclovir for iridocyclitis caused by herpes simplex virus. The Herpetic Eye Disease Study Group. Arch Ophthalmol 1996; 114: 1065–1072
- ▶ Wilhelmus KR, Dawson CR, Barron BA et al. Risk factors for herpes simplex virus epithelial keratitis recurring during treatment of stromal keratitis or iridocyclitis. Herpetic Eye Disease Study Group. Br J Ophthalmol 1996; 80: 969–972
- ▶ Barron BA, Gee L, Hauck WW et al. Herpetic Eye Disease Study. A controlled trial of oral acyclovir for herpes simplex stromal keratitis. Ophthalmology 1994; 101: 1871–1882
- ▶ Wilhelmus KR, Gee L, Hauck WW et al. Herpetic Eye Disease Study. A controlled trial of topical corticosteroids for herpes simplex stromal keratitis. Ophthalmology 1994; 101: 1883–1895; discussion 1895–1886
- ▶ Dawson CR, Jones DB, Kaufman HE et al. Design and organization of the herpetic eye disease study (HEDS). Curr Eye Res 1991; 10 Suppl: 105–110
- ▶ (No authors listed). Psychological stress and other potential triggers for recurrences of herpes simplex virus eye infections. Herpetic Eye Disease Study Group. Arch Ophthalmol 2000; 118: 1617–1625
- ▶ Liesegang TJ. Herpes simplex virus epidemiology and ocular importance. Cornea 2001; 20: 1–13
- ▶ Predictors of recurrent herpes simplex virus keratitis. Herpetic Eye Disease Study Group. Cornea 2001; 20: 123–128
- ▶ Sudesh S, Laibson PR. The impact of the herpetic eye disease studies on the management of herpes simplex virus ocular infections. Curr Opin Ophthalmol 1999; 10: 230–233
- ▶ Kip KE, Cohen F, Cole SR et al. Recall bias in a prospective cohort study of acute time-varying exposures: example from the herpetic eye disease study. J Clin Epidemiol 2001; 54: 482–487
- ▶ Wilhelmus KR. The treatment of herpes simplex virus epithelial keratitis. Trans Am Ophthalmol Soc 2000; 98: 505–532

GLAUCOMA

Fluorouracil Filtering Surgery Study (FFSS)

Recommended Reading

- ▶ (No authors listed). Five-year follow-up of the Fluorouracil Filtering Surgery Study. The Fluorouracil Filtering Surgery Study Group. Am J Ophthalmol 1996; 121: 349–366
- ▶ (No authors listed). Risk factors for suprachoroidal hemorrhage after filtering surgery. The Fluorouracil Filtering Surgery Study Group. Am J Ophthalmol 1992; 113: 501–507
- ▶ Van Buskirk EM. Five-year follow-up of the Fluorouracil Filtering Surgery Study. Am J Ophthalmol 1996; 122: 751–752

Additional Background Reading

- ▶ (No authors listed). Three-year follow-up of the Fluorouracil Filtering Surgery Study. Am J Ophthalmol 1993; 115: 82–92
- ▶ (No authors listed). Fluorouracil Filtering Surgery Study one-year follow-up. The Fluorouracil Filtering Surgery Study Group. Am J Ophthalmol 1989; 108: 625–635

Normal Tension Glaucoma Study

Recommended Reading

- ▶ Drance S, Anderson DR, Schulzer M. Risk factors for progression of visual field abnormalities in normal-tension glaucoma. *Am J Ophthalmol* 2001; 131: 699–708
- ▶ Drance SM. The Collaborative Normal-Tension Glaucoma Study and some of its lessons. *Can J Ophthalmol* 1999; 34: 1–6

Additional Background Reading

- ▶ Bayer AU, Erb C. Short wavelength automated perimetry, frequency doubling technology perimetry, and pattern electroretinography for prediction of progressive glaucomatous standard visual field defects. *Ophthalmology* 2002; 109: 1009–1017
- ▶ Schulzer M. Errors in the diagnosis of visual field progression in normal-tension glaucoma. *Ophthalmology* 1994; 101: 1589–1594; discussion 1595

Ocular Hypertension Treatment Study (OHTS)

Recommended Reading

- ▶ Kass MA, Heuer DK, Higginbotham EJ et al. The Ocular Hypertension Treatment Study: a randomized trial determines that topical ocular hypotensive medication delays or prevents the onset of primary open-angle glaucoma. *Arch Ophthalmol* 2002; 120: 701–713; discussion 829–730
- ▶ Palmberg P. Answers from the ocular hypertension treatment study. *Arch Ophthalmol* 2002; 120: 829–830

Additional Background Reading

- ▶ Gordon MO, Beiser JA, Brandt JD et al. The Ocular Hypertension Treatment Study: baseline factors that predict the onset of primary open-angle glaucoma. *Arch Ophthalmol* 2002; 120: 714–720; discussion 829–830
- ▶ Keltner JL, Johnson CA, Quigg JM et al. Confirmation of visual field abnormalities in the Ocular Hypertension Treatment Study. Ocular Hypertension Treatment Study Group. *Arch Ophthalmol* 2000; 118: 1187–1194
- ▶ Kass MA. The Ocular Hypertension Treatment Study. *J Glaucoma* 1994; 3: 97–100

Glaucoma Laser Trial (GLT) and Glaucoma Laser Trial Follow-up Study (GLTFS)

Recommended Reading

- ▶ (No authors listed). The Glaucoma Laser Trial (GLT) and glaucoma laser trial follow-up study: 7. Results. Glaucoma Laser Trial Research Group. *Am J Ophthalmol* 1995; 120: 718–731
- ▶ (No authors listed). The Glaucoma Laser Trial (GLT). 2. Results of argon laser trabeculoplasty versus topical medicines. The Glaucoma Laser Trial Research Group. *Ophthalmology* 1990; 97: 1403–1413

Additional Background Reading

- ▶ (No authors listed). The Glaucoma Laser Trial (GLT): 6. Treatment group differences in visual field changes. Glaucoma Laser Trial Research Group. *Am J Ophthalmol* 1995; 120: 10–22
- ▶ (No authors listed). The Glaucoma Laser Trial (GLT): 5. Subgroup differences at enrollment. Glaucoma Laser Trial Research Group. *Ophthalmic Surg* 1993; 24: 232–240
- ▶ (No authors listed). The Glaucoma Laser Trial (GLT): 3. Design and methods. Glaucoma Laser Trial Research Group. *Control Clin Trials* 1991; 12: 504–524

- ▶ (No authors listed). The Glaucoma Laser Trial: 4. Contralateral effects of timolol on the intraocular pressure of eyes treated with ALT. GLT Research Group. *Ophthalmic Surg* 1991; 22: 324–329
- ▶ (No authors listed). The Glaucoma Laser Trial. I. Acute effects of argon laser trabeculoplasty on intraocular pressure. Glaucoma Laser Trial Research Group. *Arch Ophthalmol* 1989; 107: 1135–1142
- ▶ Richardson LE. Argon laser trabeculoplasty: a review. *J Am Optom Assoc* 1992; 63: 252–256
- ▶ Lichter PR. Practice implications of the Glaucoma Laser Trial. *Ophthalmology* 1990; 97: 1401–1402

Optic Neuritis Treatment Trial (ONTT)

Recommended Reading

- ▶ Beck RW, Trobe JD. The Optic Neuritis Treatment Trial. Putting the results in perspective. The Optic Neuritis Study Group. *J Neuroophthalmol* 1995; 15: 131–135
- ▶ Beck RW, Arrington J, Murtagh FR, Cleary PA, Kaufman DI. Brain magnetic resonance imaging in acute optic neuritis. Experience of the Optic Neuritis Study Group. *Arch Neurol* 1993; 50: 841–846
- ▶ Beck RW, Cleary PA, Trobe JD et al. The effect of corticosteroids for acute optic neuritis on the subsequent development of multiple sclerosis. The Optic Neuritis Study Group. *N Engl J Med* 1993; 329: 1764–1769
- ▶ Beck RW, Cleary PA, Anderson MM Jr. et al. A randomized, controlled trial of corticosteroids in the treatment of acute optic neuritis. The Optic Neuritis Study Group. *N Engl J Med* 1992; 326: 581–588
- ▶ (No authors listed). The 5-year risk of MS after optic neuritis. Experience of the optic neuritis treatment trial. 1997. *Neurology* 2001 Dec; 57(12 Suppl 5): S36–45
- ▶ Fang JP, Lin RH, Donahue SP. Recovery of visual field function in the optic neuritis treatment trial. *Am J Ophthalmol* 1999; 128: 566–572
- ▶ Trobe JD, Sieving PC, Guire KE, Fendrick AM. The impact of the optic neuritis treatment trial on the practices of ophthalmologists and neurologists. *Ophthalmology* 1999; 106: 2047–2053
- ▶ (No authors listed). Visual function 5 years after optic neuritis: experience of the Optic Neuritis Treatment Trial. The Optic Neuritis Study Group. *Arch Ophthalmol* 1997; 115: 1545–1552
- ▶ (No authors listed). The 5-year risk of MS after optic neuritis. Experience of the optic neuritis treatment trial. Optic Neuritis Study Group. *Neurology* 1997; 49: 1404–1413
- ▶ Cleary PA, Beck RW, Bourque LB, Backlund JC, Miskala PH. Visual symptoms after optic neuritis. Results from the Optic Neuritis Treatment Trial. *J Neuroophthalmol* 1997; 17: 18–23; quiz 24–8

Additional Background Reading

- ▶ Keltner JL, Johnson CA, Spurr JO, Beck RW. Comparison of central and peripheral visual field properties in the optic neuritis treatment trial. *Am J Ophthalmol* 1999; 128: 543–55
- ▶ Anderson MM Jr., Boly LD, Beck RW. Remote clinic/patient monitoring for multicenter trials. Optic Neuritis Study Group. *Control Clin Trials* 1996; 17: 407–414
- ▶ Rolak LA, Beck RW, Paty DW et al. Cerebrospinal fluid in acute optic neuritis: experience of the optic neuritis treatment trial. *Neurology* 1996; 46: 368–372

- ▶ Trobe JD, Beck RW, Moke PS, Cleary PA. Contrast sensitivity and other vision tests in the optic neuritis treatment trial. *Am J Ophthalmol* 1996; 121: 547–553
- ▶ Beck RW. The optic neuritis treatment trial: three-year follow-up results. *Arch Ophthalmol* 1995; 113: 136–137
- ▶ Beck RW, Trobe JD. What we have learned from the Optic Neuritis Treatment Trial. *Ophthalmology* 1995; 102: 1504–1508
- ▶ Beck RW, Cleary PA, Backlund JC. The course of visual recovery after optic neuritis. Experience of the Optic Neuritis Treatment Trial. *Ophthalmology* 1994; 101: 1771–1778
- ▶ Keltner JL, Johnson CA, Spurr JO, Beck RW. Visual field profile of optic neuritis. One-year follow-up in the Optic Neuritis Treatment Trial. *Arch Ophthalmol* 1994; 112: 946–953
- ▶ Beck RW, Cleary PA. Optic neuritis treatment trial. One-year follow-up results. *Arch Ophthalmol* 1993; 111: 773–775
- ▶ Beck RW, Cleary PA. Recovery from severe visual loss in optic neuritis. *Arch Ophthalmol* 1993; 111: 300
- ▶ Beck RW, Diehl L, Cleary PA. Optic Neuritis Study Group: The Pelli-Robson Letter Chart: Normative data for young adults. *Clin Vis Sci* 1993; 8: 207–210
- ▶ Beck RW, Kupersmith MJ, Cleary PA, Katz B. Fellow eye abnormalities in acute unilateral optic neuritis. Experience of the optic neuritis treatment trial. *Ophthalmology* 1993; 100: 691–697; discussion 697–698
- ▶ Chrousos GA, Kattah JC, Beck RW, Cleary PA. Side effects of glucocorticoid treatment. Experience of the Optic Neuritis Treatment Trial. *Jama* 1993; 269: 2110–2112
- ▶ Cleary PA, Beck RW, Anderson MM Jr. et al. Design, methods, and conduct of the Optic Neuritis Treatment Trial. *Control Clin Trials* 1993; 14: 123–142
- ▶ Keltner JL, Johnson CA, Beck RW, Cleary PA, Spurr JO. Quality control functions of the Visual Field Reading Center (VFRC) for the Optic Neuritis Treatment Trial (ONTT). *Control Clin Trials* 1993; 14: 143–159
- ▶ Beck RW. Corticosteroid treatment of optic neuritis: a need to change treatment practices. The Optic Neuritis Study Group. *Neurology* 1992; 42: 1133–1135
- ▶ Beck RW. The optic neuritis treatment trial. Implications for clinical practice. Optic Neuritis Study Group. *Arch Ophthalmol* 1992; 110: 331–332
- ▶ (No authors listed). The clinical profile of optic neuritis. Experience of the Optic Neuritis Treatment Trial. Optic Neuritis Study Group. *Arch Ophthalmol* 1991; 109: 1673–1678
- ▶ Beck RW. The Optic Neuritis Treatment Trial. *Arch Ophthalmol* 1988; 106: 1051–1053
- ▶ Ma SL, Shea JA, Galetta SL et al. Self-reported visual dysfunction in multiple sclerosis: new data from the VFQ-25 and development of an MS-specific vision questionnaire. *Am J Ophthalmol* 2002; 133: 686–692
- ▶ Ghosh A, Kelly SP, Mathews J, Cooper PN, Macdermott N. Evaluation of the management of optic neuritis: audit on the neurological and ophthalmological practice in the north west of England. *J Neurol Neurosurg Psychiatry* 2002; 72: 119–121
- ▶ Beck RW. Comparison of the ONTT intravenous group and the CHAMPS placebo group. *J Neuroophthalmol* 2001; 21: 310
- ▶ Long DT, Beck RW, Moke PS et al. The SKILL Card test in optic neuritis: experience of the Optic Neuritis Treatment Trial. Smith-Kettlewell Institute Low Luminance. Optic Neuritis Study Group. *J Neuroophthalmol* 2001; 21: 124–131
- ▶ Hauser SL, Oksenberg JR, Lincoln R et al. Interaction between HLA-DR2 and abnormal brain MRI in optic neuritis and early MS. Optic Neuritis Study Group. *Neurology* 2000; 54: 1859–1861
- ▶ Cole SR, Beck RW, Moke PS, Gal RL, Long DT. The National Eye Institute Visual Function Questionnaire: experience of the ONTT. Optic Neuritis Treatment Trial. *Invest Ophthalmol Vis Sci* 2000; 41: 1017–1021
- ▶ Fang JP, Donahue SP, Lin RH. Global visual field involvement in acute unilateral optic neuritis. *Am J Ophthalmol* 1999; 128: 554–565
- ▶ Arnold AC. Visual field defects in the optic neuritis treatment trial: central vs peripheral, focal vs global. *Am J Ophthalmol* 1999; 128: 632–634
- ▶ Wakakura M, Minei-Higa R, Oono S et al. Baseline features of idiopathic optic neuritis as determined by a multicenter treatment trial in Japan. Optic Neuritis Treatment Trial Multicenter Cooperative Research Group (ONMRG). *Jpn J Ophthalmol* 1999; 43: 127–132
- ▶ Cole SR, Beck RW, Moke PS, Kaufman DI, Tourtellotte WW. The predictive value of CSF oligoclonal banding for MS 5 years after optic neuritis. Optic Neuritis Study Group. *Neurology* 1998; 51: 885–887
- ▶ Phillips PH, Newman NJ, Lynn MJ. Optic neuritis in African Americans. *Arch Neurol* 1998; 55: 186–192
- ▶ Schneck ME, Haegerstrom-Portnoy G. Color vision defect type and spatial vision in the optic neuritis treatment trial. *Invest Ophthalmol Vis Sci* 1997; 38: 2278–2289
- ▶ Swartz NG, Beck RW, Savino PJ et al. Pain in anterior ischemic optic neuropathy. *J Neuroophthalmol* 1995; 15: 9–10
- ▶ Wray SH. Optic neuritis: guidelines. *Curr Opin Neurol* 1995; 8: 72–76
- ▶ Arnold AC. Updated recommendations from the Optic Neuritis Treatment Trial. *West J Med* 1994; 161: 593–594
- ▶ Trobe JD. High-dose corticosteroid regimen retards development of multiple sclerosis in optic neuritis treatment trial. *Arch Ophthalmol* 1994; 112: 35–36

Ischemic Optic Neuropathy Decompression Trial (IONDT)

Recommended Reading

- ▶ (No authors listed). Optic nerve decompression surgery for nonarteritic anterior ischemic optic neuropathy (NAION) is not effective and may be harmful. The Ischemic Optic Neuropathy Decompression Trial Research Group. *Jama* 1995; 273: 625–632
- ▶ Newman NJ, Scherer R, Langenberg P et al. The fellow eye in NAION: report from the ischemic optic neuropathy decompression trial follow-up study. *Am J Ophthalmol* 2002; 134: 317–328

Additional Background Reading

- ▶ (No authors listed). The ischemic optic neuropathy decompression trial (IONDT): design and methods. *Control Clin Trials* 1998; 19: 276–296
- ▶ (No authors listed). Characteristics of patients with nonarteritic anterior ischemic optic neuropathy eligible for the Ischemic Optic Neuropathy Decompression Trial. *Arch Ophthalmol* 1996; 114: 1366–1374
- ▶ (No authors listed). Ischemic Optic Neuropathy Decompression Trial: twenty-four-month update. *Arch Ophthalmol* 2000; 118: 793–798

RETINA

- ▶ Studies of the Ocular Complications of AIDS (SOCA)
- ▶ Longitudinal Study of Ocular Complications of AIDS (LSOCA)
- ▶ Ganciclovir-Cidofovir CMV Retinitis Trial (GCCRT)
- ▶ Cytomegalovirus Retinitis Retreatment Trial (CRRT)
- ▶ Foscarnet-Ganciclovir CMV Retinitis Trial (FGCRT)
- ▶ HPMPV Peripheral CMV Retinitis Trial (HPCRT)
- ▶ Monoclonal Antibody CMV Retinitis Trial (MACRT)

Recommended Reading

- ▶ Kempen JH, Jabs DA, Wilson LA et al. Risk of vision loss in patients with cytomegalovirus retinitis and the acquired immunodeficiency syndrome. *Arch Ophthalmol* 2003; 121: 466–476
- ▶ Vitrevene Study Group. A randomized controlled clinical trial of intravitreal foscarnet for treatment of newly diagnosed peripheral cytomegalovirus retinitis in patients with AIDS. *Am J Ophthalmol* 2002; 133: 467–474
- ▶ Vitrevene Study Group. Randomized dose-comparison studies of intravitreal foscarnet for treatment of cytomegalovirus retinitis that has reactivated or is persistently active despite other therapies in patients with AIDS. *Am J Ophthalmol* 2002; 133: 475–483
- ▶ Vitrevene Study Group. Safety of intravitreal foscarnet for treatment of cytomegalovirus retinitis in patients with AIDS. *Am J Ophthalmol* 2002; 133: 484–498
- ▶ Jabs DA, Van Natta ML, Kempen JH et al. Characteristics of patients with cytomegalovirus retinitis in the era of highly active antiretroviral therapy. *Am J Ophthalmol* 2002; 133: 48–61
- ▶ Jabs DA, Griffiths PD. Foscarnet for the treatment of cytomegalovirus retinitis. *Am J Ophthalmol* 2002; 133: 552–556
- ▶ Martin DF, Sierra-Madero J, Walmsley S et al. A controlled trial of valganciclovir as induction therapy for cytomegalovirus retinitis. *N Engl J Med* 2002; 346: 1119–1126
- ▶ Kempen JH, Jabs DA, Dunn JP, West SK, Tonascia J. Retinal detachment risk in cytomegalovirus retinitis related to the acquired immunodeficiency syndrome. *Arch Ophthalmol* 2001; 119: 33–40
- ▶ Martin DF, Kuppermann BD, Wolitz RA et al. Oral ganciclovir for patients with cytomegalovirus retinitis treated with a ganciclovir implant. Roche Ganciclovir Study Group. *N Engl J Med* 1999; 340: 1063–1070
- ▶ Jabs DA, Bolton SG, Dunn JP, Palestine AG. Discontinuing anticytomegalovirus therapy in patients with immune reconstitution after combination antiretroviral therapy. *Am J Ophthalmol* 1998; 126: 817–822
- ▶ Jabs DA, Bartlett JG. AIDS and ophthalmology: a period of transition. *Am J Ophthalmol* 1997; 124: 227–233
- ▶ Musch DC, Martin DF, Gordon JF, Davis MD, Kuppermann BD. Treatment of cytomegalovirus retinitis with a sustained-release ganciclovir implant. The Ganciclovir Implant Study Group. *N Engl J Med* 1997; 337: 83–90
- ▶ Jabs DA. Ocular manifestations of HIV infection. *Trans Am Ophthalmol Soc* 1995; 93: 623–683
- ▶ (No authors listed). Combination foscarnet and ganciclovir therapy vs monotherapy for the treatment of relapsed cytomegalovirus retinitis in patients with AIDS. The Cytomegalovirus Retreatment Trial. The Studies of Ocular Complications of AIDS Research Group in Collaboration with the AIDS Clinical Trials Group. *Arch Ophthalmol* 1996; 114: 23–33
- ▶ (No authors listed). Cytomegalovirus (CMV) culture results, drug resistance, and clinical outcome in patients with AIDS

and CMV retinitis treated with foscarnet or ganciclovir. Studies of Ocular Complications of AIDS (SOCA) in collaboration with the AIDS Clinical Trial Group. *J Infect Dis* 1997; 176: 50–58

- ▶ (No authors listed). Foscarnet-Ganciclovir Cytomegalovirus Retinitis Trial. 5. Clinical features of cytomegalovirus retinitis at diagnosis. Studies of ocular complications of AIDS Research Group in collaboration with the AIDS Clinical Trials Group. *Am J Ophthalmol* 1997; 124: 141–157
- ▶ (No authors listed). Morbidity and toxic effects associated with ganciclovir or foscarnet therapy in a randomized cytomegalovirus retinitis trial. Studies of ocular complications of AIDS Research Group, in collaboration with the AIDS Clinical Trials Group. *Arch Intern Med* 1995; 155: 65–74
- ▶ (No authors listed). Foscarnet-Ganciclovir Cytomegalovirus Retinitis Trial. 4. Visual outcomes. Studies of Ocular Complications of AIDS Research Group in collaboration with the AIDS Clinical Trials Group. *Ophthalmology* 1994; 101: 1250–1261
- ▶ (No authors listed). Mortality in patients with the acquired immunodeficiency syndrome treated with either foscarnet or ganciclovir for cytomegalovirus retinitis. Studies of Ocular Complications of AIDS Research Group, in collaboration with the AIDS Clinical Trials Group. *N Engl J Med* 1992; 326: 213–220
- ▶ (No authors listed). Parenteral cidofovir for cytomegalovirus retinitis in patients with AIDS: the HPMPV peripheral cytomegalovirus retinitis trial. A randomized, controlled trial. Studies of Ocular complications of AIDS Research Group in Collaboration with the AIDS Clinical Trials Group. *Ann Intern Med* 1997; 126: 264–274

Additional Background Reading

- ▶ (No authors listed). Rhegmatogenous retinal detachment in patients with cytomegalovirus retinitis: the Foscarnet-Ganciclovir Cytomegalovirus Retinitis Trial. The Studies of Ocular Complications of AIDS (SOCA) Research Group in Collaboration with the AIDS Clinical Trials Group (ACTG). *Am J Ophthalmol* 1997; 124: 61–70
- ▶ (No authors listed). Assessment of cytomegalovirus retinitis. Clinical evaluation vs centralized grading of fundus photographs. Studies of Ocular Complications of AIDS Research Group, AIDS Clinical Trials Group. *Arch Ophthalmol* 1996; 114: 791–805
- ▶ (No authors listed). Clinical vs photographic assessment of treatment of cytomegalovirus retinitis. Foscarnet-Ganciclovir Cytomegalovirus Retinitis Trial Report 8. Studies of Ocular Complications of AIDS Research Group, AIDS Clinical Trials Group. *Arch Ophthalmol* 1996; 114: 848–855
- ▶ Wu AW, Coleson LC, Holbrook J, Jabs DA. Measuring visual function and quality of life in patients with cytomegalovirus retinitis. Development of a questionnaire. Studies of Ocular Complication of AIDS Research Group. *Arch Ophthalmol* 1996; 114: 841–847
- ▶ (No authors listed). Antiviral effects of foscarnet and ganciclovir therapy on human immunodeficiency virus p24 antigen in patients with AIDS and cytomegalovirus retinitis. Studies of Ocular Complications of AIDS Research Group in collaboration with AIDS Clinical Trials Group. *J Infect Dis* 1995; 172: 613–621
- ▶ (No authors listed). Studies of ocular complications of AIDS Foscarnet-Ganciclovir Cytomegalovirus Retinitis Trial:

1. Rationale, design, and methods. AIDS Clinical Trials Group (ACTG). *Control Clin Trials* 1992; 13: 22–39

- ▶ Holbrook JT, Meinert CL, Jabs DA. Patient notification and follow-up after suspension of treatment protocols. experience from four clinical trials of treatments for AIDS-related CMV retinitis. *Control Clin Trials* 2001; 22: 62–68
- ▶ Holbrook JT, Davis MD, Hubbard LD et al. Risk factors for advancement of cytomegalovirus retinitis in patients with acquired immunodeficiency syndrome. *Studies of Ocular Complications of AIDS Research Group. Arch Ophthalmol* 2000; 118: 1196–1204
- ▶ (No authors listed). Long-term follow-up of patients with AIDS treated with parenteral cidofovir for cytomegalovirus retinitis: the HPMPC Peripheral Cytomegalovirus Retinitis Trial. *The Studies of Ocular Complications of AIDS Research Group in collaboration with the AIDS Clinical Trials Group. Aids* 2000; 14: 1571–1581
- ▶ (No authors listed). MSL-109 adjuvant therapy for cytomegalovirus retinitis in patients with acquired immunodeficiency syndrome: the Monoclonal Antibody Cytomegalovirus Retinitis Trial. *The Studies of Ocular Complications of AIDS Research Group. AIDS Clinical Trials Group. Arch Ophthalmol* 1997; 115: 1528–1536
- ▶ (No authors listed). SOCA research group stops enrollment. *Studies of the Ocular Complications of AIDS. AIDS Patient Care STDS* 1996; 10: 188
- ▶ Jacobson MA. Current management of cytomegalovirus disease in patients with AIDS. *AIDS Res Hum Retroviruses* 1994; 10: 917–923

Branch Vein Occlusion Studies (BVOS)

Recommended Reading

- ▶ (No authors listed). Argon laser scatter photocoagulation for prevention of neovascularization and vitreous hemorrhage in branch vein occlusion. A randomized clinical trial. *Branch Vein Occlusion Study Group. Arch Ophthalmol* 1986; 104: 34–41
- ▶ (No authors listed). Argon laser photocoagulation for macular edema in branch vein occlusion. *The Branch Vein Occlusion Study Group. Am J Ophthalmol* 1984; 98: 271–282
- ▶ Brown GC, Brown MM, Sharma S, Busbee B, Brown H. Incremental cost-effectiveness of laser therapy for visual loss secondary to branch retinal vein occlusion. *Ophthalmic Epidemiol* 2002; 9: 1–10

Additional Background Reading

- ▶ Barbazetto IA, Schmidt-Erfurth UM. Evaluation of functional defects in branch retinal vein occlusion before and after laser treatment with scanning laser perimetry. *Ophthalmology* 2000; 107: 1089–1098
- ▶ Saxena S. Laser photocoagulation in retinal vein occlusion: branch vein occlusion study and central vein occlusion study recommendations. *Indian J Ophthalmol* 1997; 45: 125–128. Comment: 1997; 45: 261–262
- ▶ Cousins SW, Flynn HW Jr., Clarkson JG. Macroaneurysms associated with retinal branch vein occlusion. *Am J Ophthalmol* 1990; 109: 567–570
- ▶ Finkelstein D. Argon laser photocoagulation for macular edema in branch vein occlusion. *Ophthalmology* 1986; 93: 975–977
- ▶ (No authors listed). Branch vein occlusion study. *Invest Ophthalmol Vis Sci* 1979; 18: 1097

Macular Photocoagulation Study (MPS)

Recommended Reading

- ▶ (No authors listed). Risk factors for choroidal neovascularization in the second eye of patients with juxtafoveal or subfoveal choroidal neovascularization secondary to age-related macular degeneration. *Macular Photocoagulation Study Group. Arch Ophthalmol* 1997; 115: 741–747
- ▶ (No authors listed). Laser photocoagulation for juxtafoveal choroidal neovascularization. Five-year results from randomized clinical trials. *Macular Photocoagulation Study Group. Arch Ophthalmol* 1994; 112: 500–509
- ▶ (No authors listed). Five-year follow-up of fellow eyes of patients with age-related macular degeneration and unilateral extrafoveal choroidal neovascularization. *Macular Photocoagulation Study Group. Arch Ophthalmol* 1993; 111: 1189–1199
- ▶ (No authors listed). Laser photocoagulation of subfoveal neovascular lesions of age-related macular degeneration. Updated findings from two clinical trials. *Macular Photocoagulation Study Group. Arch Ophthalmol* 1993; 111: 1200–1209
- ▶ (No authors listed). Argon laser photocoagulation for neovascular maculopathy. Five-year results from randomized clinical trials. *Macular Photocoagulation Study Group. Arch Ophthalmol* 1991; 109: 1109–1114
- ▶ No authors listed. Krypton laser photocoagulation for neovascular lesions of age-related macular degeneration. Results of a randomized clinical trial. *Macular Photocoagulation Study Group. Arch Ophthalmol* 1990; 108: 816–824
- ▶ (No authors listed). Persistent and recurrent neovascularization after krypton laser photocoagulation for neovascular lesions of age-related macular degeneration. *Macular Photocoagulation Study Group. Arch Ophthalmol* 1990; 108: 825–831
- ▶ Bressler SB, Maguire MG, Bressler NM, Fine SL. Relationship of drusen and abnormalities of the retinal pigment epithelium to the prognosis of neovascular macular degeneration. *The Macular Photocoagulation Study Group. Arch Ophthalmol* 1990; 108: 1442–1447
- ▶ Chamberlin JA, Bressler NM, Bressler SB et al. The use of fundus photographs and fluorescein angiograms in the identification and treatment of choroidal neovascularization in the Macular Photocoagulation Study. *The Macular Photocoagulation Study Group. Ophthalmology* 1989; 96: 1526–1534
- ▶ (No authors listed). Krypton laser photocoagulation for neovascular lesions of ocular histoplasmosis. Results of a randomized clinical trial. *Macular Photocoagulation Study Group. Arch Ophthalmol* 1987; 105: 1499–1507
- ▶ (No authors listed). Recurrent choroidal neovascularization after argon laser photocoagulation for neovascular maculopathy. *Macular Photocoagulation Study Group. Arch Ophthalmol* 1986; 104: 503–512
- ▶ (No authors listed). Argon laser photocoagulation for neovascular maculopathy. Three-year results from randomized clinical trials. *Macular Photocoagulation Study Group. Arch Ophthalmol* 1986; 104: 694–701
- ▶ (No authors listed). Argon laser photocoagulation for ocular histoplasmosis. Results of a randomized clinical trial. *Arch Ophthalmol* 1983; 101: 1347–1357
- ▶ (No authors listed). Argon laser photocoagulation for idiopathic neovascularization. Results of a randomized clinical trial. *Arch Ophthalmol* 1983; 101: 1358–1361

- ▶ (No authors listed). Argon laser photocoagulation for senile macular degeneration. Results of a randomized clinical trial. *Arch Ophthalmol* 1982; 100: 912–918
- ▶ Zimmer-Galler IE, Bressler NM, Bressler SB. Treatment of choroidal neovascularization: updated information from recent macular photocoagulation study group reports. *Int Ophthalmol Clin* 1995; 35: 37–57

Additional Background Reading

- ▶ (No authors listed). Occult choroidal neovascularization. Influence on visual outcome in patients with age-related macular degeneration. Macular Photocoagulation Study Group. *Arch Ophthalmol* 1996; 114: 400–412
- ▶ (No authors listed). Five-year follow-up of fellow eyes of individuals with ocular histoplasmosis and unilateral extrafoveal or juxtafoveal choroidal neovascularization. Macular Photocoagulation Study Group. *Arch Ophthalmol* 1996; 114: 677–688
- ▶ (No authors listed). Laser photocoagulation for neovascular lesions nasal to the fovea. Results from clinical trials for lesions secondary to ocular histoplasmosis or idiopathic causes. Macular Photocoagulation Study Group. *Arch Ophthalmol* 1995; 113: 56–61
- ▶ (No authors listed). The influence of treatment extent on the visual acuity of eyes treated with Krypton laser for juxtafoveal choroidal neovascularization. Macular Photocoagulation Study Group. *Arch Ophthalmol* 1995; 113: 190–194
- ▶ (No authors listed). Visual outcome after laser photocoagulation for subfoveal choroidal neovascularization secondary to age-related macular degeneration. The influence of initial lesion size and initial visual acuity. Macular Photocoagulation Study Group. *Arch Ophthalmol* 1994; 112: 480–488
- ▶ (No authors listed). Persistent and recurrent neovascularization after laser photocoagulation for subfoveal choroidal neovascularization of age-related macular degeneration. Macular Photocoagulation Study Group. *Arch Ophthalmol* 1994; 112: 489–499
- ▶ (No authors listed). Evaluation of argon green vs krypton red laser for photocoagulation of subfoveal choroidal neovascularization in the macular photocoagulation study. Macular Photocoagulation Study (MPS) Group. *Arch Ophthalmol* 1994; 112: 1176–1184
- ▶ Birch DG, Anderson JL, Fish GE, Jost BF. Pattern-reversal electroretinographic follow-up of laser photocoagulation for subfoveal neovascular lesions in age-related macular degeneration. *Am J Ophthalmol* 1993; 116: 148–155
- ▶ Fine SL. The case for treating subfoveal neovascularization in patients with age-related macular degeneration, Franklin RM (ed): *Retina and Vitreous. Proceedings of the Symposium on Retina and Vitreous*, New Orleans Academy of Ophthalmology, New York, Kugler Publications: 1993; 29–30
- ▶ Birch DG, Anderson JL, Fish GE, Jost BF. Pattern-reversal electroretinographic acuity in untreated eyes with subfoveal neovascular membranes. *Invest Ophthalmol Vis Sci* 1992; 33: 2097–2104
- ▶ Orr PR, Blackhurst DW, Hawkins BS. Patient and clinic factors predictive of missed visits and inactive status in a multicenter clinical trial. The Macular Photocoagulation Study Group. *Control Clin Trials* 1992; 13: 40–49
- ▶ Bressler NM, Bressler SB, Alexander J et al. Loculated fluid. A previously undescribed fluorescein angiographic finding in choroidal neovascularization associated with macular degeneration. Macular Photocoagulation Study Reading Center. *Arch Ophthalmol* 1991; 109: 211–215
- ▶ (No authors listed). Laser photocoagulation of subfoveal neovascular lesions in age-related macular degeneration. Results of a randomized clinical trial. Macular Photocoagulation Study Group. *Arch Ophthalmol* 1991; 109: 1220–1231
- ▶ (No authors listed). Laser photocoagulation of subfoveal recurrent neovascular lesions in age-related macular degeneration. Results of a randomized clinical trial. Macular Photocoagulation Study Group. *Arch Ophthalmol* 1991; 109: 1232–1241
- ▶ (No authors listed). Subfoveal neovascular lesions in age-related macular degeneration. Guidelines for evaluation and treatment in the macular photocoagulation study. Macular Photocoagulation Study Group. *Arch Ophthalmol* 1991; 109: 1242–1257
- ▶ Hawkins BS, Prior MJ, Fisher MR, Blackhurst DW. Relationship between rate of patient enrollment and quality of clinical center performance in two multicenter trials in ophthalmology. *Control Clin Trials* 1990; 11: 374–394
- ▶ (No authors listed). Krypton laser photocoagulation for idiopathic neovascular lesions. Results of a randomized clinical trial. Macular Photocoagulation Study Group. *Arch Ophthalmol* 1990; 108: 832–837
- ▶ Blackhurst DW, Maguire MG. Reproducibility of refraction and visual acuity measurement under a standard protocol. The Macular Photocoagulation Study Group. *Retina* 1989; 9: 163–169
- ▶ (No authors listed). Persistent and recurrent neovascularization after krypton laser photocoagulation for neovascular lesions of ocular histoplasmosis. Macular Photocoagulation Study Group. *Arch Ophthalmol* 1989; 107: 344–352
- ▶ Hillis A, Maguire M, Hawkins BS, Newhouse MM. The Markov process as a general method for nonparametric analysis of right-censored medical data. *J Chronic Dis* 1986; 39: 595–604
- ▶ Fine SL. Early detection of extrafoveal neovascular membranes by daily central field evaluation. *Ophthalmology* 1985; 92: 603–609
- ▶ (No authors listed). Changing the protocol: a case report from the Macular Photocoagulation Study. Macular Photocoagulation Study Group. *Control Clin Trials* 1984; 5: 203–216
- ▶ Gottfredsdottir MS, Sverrisson T, Musch DC, Stefansson E. Age related macular degeneration in monozygotic twins and their spouses in Iceland. *Acta Ophthalmol Scand* 1999; 77: 422–425
- ▶ (No authors listed). Age-related macular degeneration. The Macular Photocoagulation Study. *Am J Ophthalmol* 1984; 98: 376–377
- ▶ Freund KB, Yannuzzi LA, Sorenson JA. Age-related macular degeneration and choroidal neovascularization. *Am J Ophthalmol* 1993; 115: 786–791
- ▶ Jampol LM. Hypertension and visual outcome in the macular photocoagulation study. *Arch Ophthalmol* 1991; 109: 789–790
- ▶ Jost BF, Alexander MF, Maguire MG et al. Laser treatment for choroidal neovascularization outside randomized clinical trials. *Arch Ophthalmol* 1988; 106: 357–361
- ▶ Fine SL. Macular photocoagulation study. *Arch Ophthalmol* 1980; 98: 832
- ▶ Fine SL, Hawkins B, Maguire M. Macular photocoagulation study. *Arch Ophthalmol* 1984; 102: 1583

- ▶ Jampol LM, Tielsch J. Race, macular degeneration, and the Macular Photocoagulation Study. *Arch Ophthalmol* 1992; 110: 1699 – 1700
 - ▶ Moisseiev J, Alhalel A, Masuri R, Treister G. The impact of the macular photocoagulation study results on the treatment of exudative age-related macular degeneration. *Arch Ophthalmol* 1995; 113: 185 – 189
 - ▶ Beatty S, Au Eong KG, McLeod D, Bishop PN. Photocoagulation of subfoveal choroidal neovascular membranes in age related macular degeneration: the impact of the macular photocoagulation study in the United Kingdom and Republic of Ireland. *Br J Ophthalmol* 1999; 83: 1103 – 1104
 - ▶ Custis PH, Bressler SB, Bressler NM. Laser management of subfoveal choroidal neovascularization in age-related macular degeneration. *Curr Opin Ophthalmol* 1993; 4: 7 – 18
 - ▶ Dyer DS, Bressler SB, Bressler NM. The role of laser wavelength in the treatment of vitreoretinal diseases. *Curr Opin Ophthalmol* 1994; 5: 35 – 43
 - ▶ Bergink GJ, Deutman AF, van den Broek JF, van Daal WA, van der Maazen RW. Radiation therapy for subfoveal choroidal neovascular membranes in age-related macular degeneration. A pilot study. *Graefes Arch Clin Exp Ophthalmol* 1994; 32: 591 – 598
 - ▶ Gelfand YA, Linn S, Miller B. The application of the macular photocoagulation study eligibility criteria for laser treatment in age-related macular degeneration. *Ophthalmic Surg Lasers* 1997; 28: 823 – 827
 - ▶ Spaide RF, Guyer DR, McCormick B et al. External beam radiation therapy for choroidal neovascularization. *Ophthalmology* 1998; 105: 24 – 30
 - ▶ Ormerod LD, Puklin JE, Frank RN. Long-term outcomes after the surgical removal of advanced subfoveal neovascular membranes in age-related macular degeneration. *Ophthalmology* 1994; 101: 1201 – 1210
 - ▶ Avvad FK, Duker JS, Reichel E, Margolis TI, Puliafito CA. The digital indocyanine green videoangiography characteristics of well-defined choroidal neovascularization. *Ophthalmology* 1995; 102: 401 – 405
 - ▶ Yannuzzi LA. A new standard of care for laser photocoagulation of subfoveal choroidal neovascularization secondary to age-related macular degeneration. Data revisited. *Arch Ophthalmol* 1994; 112: 462 – 464
 - ▶ Tiedeman JS. Treatment of subfoveal choroidal neovascularization. *Arch Ophthalmol* 1995; 113: 137 – 138
 - ▶ Hawkins WR. Visual prognosis of eyes with submacular choroidal neovascularization. *Arch Ophthalmol* 1994; 112: 874 – 875
 - ▶ Fine SL, Hawkins BS, Maguire MG. Krypton Laser photocoagulation for neovascular lesions of age-related macular degeneration. *Arch Ophthalmol* 1991; 109: 614 – 615
 - ▶ Tornambe PE, Poliner LS. Partial ablation of neovascular membranes involving the fovea. *Arch Ophthalmol* 1989; 107: 955 – 956
 - ▶ Wolfe JA, Horton MB, McAteer MB, Szuter CF, Clayton T. Race, macular degeneration, and diabetic maculopathy. *Arch Ophthalmol* 1993; 111: 1603 – 1604
 - ▶ Chakravarthy U, Hart P, Finger P. External beam radiation therapy for CNV. *Ophthalmology* 1998; 105: 1790 – 1791; author reply 1791 – 1792
 - ▶ Beaumont P, Chang A. External beam radiation therapy for CNV. *Ophthalmology* 1998; 105: 1792 – 1793; author reply 1793 – 1794
 - ▶ Schachat AP. Management of subfoveal choroidal neovascularization. *Arch Ophthalmol* 1991; 109: 1217 – 1218
- ### Age-Related Eye Disease Study (AREDS)
- #### Recommended Reading
- ▶ Clemons TE, Chew EY, Bressler SB, McBee W. National Eye Institute Visual Function Questionnaire in the Age-Related Eye Disease Study (AREDS): AREDS Report No. 10. *Arch Ophthalmol* 2003; 121: 211 – 217
 - ▶ Age-Related Eye Disease Study Research Group. The effect of five-year zinc supplementation on serum zinc, serum cholesterol and hematocrit in persons randomly assigned to treatment group in the age-related eye disease study: AREDS Report No. 7. *J Nutr* 2002; 132: 697 – 702
 - ▶ Age-Related Eye Disease Study Research Group. A randomized, placebo-controlled, clinical trial of high-dose supplementation with vitamins C and E and beta carotene for age-related cataract and vision loss: AREDS report no. 9. *Arch Ophthalmol* 2001; 119: 1439 – 1452
 - ▶ Age-Related Eye Disease Study Research Group. A randomized, placebo-controlled, clinical trial of high-dose supplementation with vitamins C and E, beta carotene, and zinc for age-related macular degeneration and vision loss: AREDS report no. 8. *Arch Ophthalmol* 2001; 119: 1417 – 1436
 - ▶ Age-Related Eye Disease Study Research Group. The Age-Related Eye Disease Study system for classifying age-related macular degeneration from stereoscopic color fundus photographs: the Age-Related Eye Disease Study Report Number 6. *Am J Ophthalmol* 2001; 132: 668 – 681
 - ▶ Age-Related Eye Disease Study Research Group. The age-related eye disease study (AREDS) system for classifying cataracts from photographs: AREDS report no. 4. *Am J Ophthalmol* 2001; 131: 167 – 175
 - ▶ (No authors listed). Risk factors associated with age-related nuclear and cortical cataract : a case-control study in the Age-Related Eye Disease Study, AREDS Report No. 5. *Ophthalmology* 2001; 108: 1400 – 1408
 - ▶ (No authors listed). The Age-Related Eye Disease Study: a clinical trial of zinc and antioxidants – Age-Related Eye Disease Study Report No. 2. *J Nutr* 2000; 130: 1516S – 1519S
 - ▶ (No authors listed). Risk factors associated with age-related macular degeneration. A case-control study in the age-related eye disease study: Age-Related Eye Disease Study Report Number 3. *Ophthalmology* 2000; 107: 2224 – 2232
 - ▶ (No authors listed). The Age-Related Eye Disease Study (AREDS): design implications. AREDS report no. 1. *Control Clin Trials* 1999; 20: 573 – 600
- ### Verteporfin in Photodynamic Therapy (VIP)
- #### Recommended Reading
- ▶ Blinder KJ, Blumenkranz MS, Bressler NM et al. Verteporfin therapy of subfoveal choroidal neovascularization in pathologic myopia: 2-year results of a randomized clinical trial – VIP report no. 3. *Ophthalmology* 2003; 110: 667 – 673
 - ▶ Verteporfin in Photodynamic Therapy Study Group. Verteporfin therapy of subfoveal choroidal neovascularization in age-related macular degeneration: two-year results of a randomized clinical trial including lesions with occult with no classic choroidal neovascularization – verteporfin in photo-

dynamic therapy report 2. *Am J Ophthalmol* 2001; 131: 541–560

- ▶ Verteporfin in Photodynamic Therapy Study Group. Photodynamic therapy of subfoveal choroidal neovascularization in pathologic myopia with verteporfin. 1-year results of a randomized clinical trial – VIP report no. 1. *Ophthalmology* 2001; 108: 841–852
- ▶ Verteporfin Roundtable 2000 and 2001 Participants, Treatment of age-related macular degeneration with photodynamic therapy (TAP) study group principal investigators, Verteporfin in photodynamic therapy (VIP) study group principal investigators. Guidelines for using verteporfin (visudyne) in photodynamic therapy to treat choroidal neovascularization due to age-related macular degeneration and other causes. *Retina* 2002; 22: 6–18

Treatment of Age-Related Macular Degeneration with Photodynamic Therapy (TAP)

Recommended Reading

- ▶ Blumenkranz MS, Bressler NM, Bressler SB et al. Verteporfin therapy for subfoveal choroidal neovascularization in age-related macular degeneration: three-year results of an open-label extension of 2 randomized clinical trials – TAP Report no. 5. *Arch Ophthalmol* 2002; 120: 1307–1314
- ▶ Rubin GS, Bressler NM. Effects of verteporfin therapy on contrast on sensitivity: Results From the Treatment of Age-Related Macular Degeneration With Photodynamic Therapy (TAP) investigation-TAP report No 4. *Retina* 2002; 22: 536–544
- ▶ Bressler NM, Arnold J, Benchaboune M et al. Verteporfin therapy of subfoveal choroidal neovascularization in patients with age-related macular degeneration: additional information regarding baseline lesion composition's impact on vision outcomes-TAP report No. 3. *Arch Ophthalmol* 2002; 120: 1443–1454
- ▶ Bressler NM. Photodynamic therapy of subfoveal choroidal neovascularization in age-related macular degeneration with verteporfin: two-year results of 2 randomized clinical trials-tap report 2. *Arch Ophthalmol* 2001; 119: 198–207
- ▶ Miller JW, Schmidt-Erfurth U, Sickenberg M et al. Photodynamic therapy with verteporfin for choroidal neovascularization caused by age-related macular degeneration: results of a single treatment in a phase 1 and 2 study. *Arch Ophthalmol* 1999; 117: 1161–1173 [Erratum in: *Arch Ophthalmol* 2000 Apr; 118: 1488]
- ▶ (No authors listed). Photodynamic therapy of subfoveal choroidal neovascularization in age-related macular degeneration with verteporfin: one-year results of 2 randomized clinical trials – TAP report. Treatment of age-related macular degeneration with photodynamic therapy (TAP) Study Group. *Arch Ophthalmol* 1999; 117: 1329–1345 [Erratum in: *Arch Ophthalmol* 2000 April; 118: 1488]

Silicone Study

Recommended Reading

- ▶ Abrams GW, Azen SP, McCuen BW, 2nd et al. Vitrectomy with silicone oil or long-acting gas in eyes with severe proliferative vitreoretinopathy: results of additional and long-term follow-up. Silicone Study report 11. *Arch Ophthalmol* 1997; 115: 335–344

- ▶ McCuen BW, 2nd, Azen SP, Stern W et al. Vitrectomy with silicone oil or perfluoropropane gas in eyes with severe proliferative vitreoretinopathy. Silicone Study Report 3. *Retina* 1993; 13: 279–284
- ▶ (No authors listed). Vitrectomy with silicone oil or sulfur hexafluoride gas in eyes with severe proliferative vitreoretinopathy: results of a randomized clinical trial. Silicone Study Report 1. *Arch Ophthalmol* 1992; 110: 770–779
- ▶ (No authors listed). Krypton laser photocoagulation for neovascular lesions of ocular histoplasmosis. Results of a randomized clinical trial. Macular Photocoagulation Study Group. *Arch Ophthalmol* 1987; 105: 1499–1507
- ▶ (No authors listed). Vitrectomy with silicone oil or perfluoropropane gas in eyes with severe proliferative vitreoretinopathy: results of a randomized clinical trial. Silicone Study Report 2. *Arch Ophthalmol* 1992; 110: 780–792
- ▶ Lean JS, Stern WH, Irvine AR, Azen SP. Classification of proliferative vitreoretinopathy used in the silicone study. The Silicone Study Group. *Ophthalmology* 1989; 96: 765–771
- ▶ Brown GC, Brown MM, Sharma S, Busbee B, Landy J. A cost-utility analysis of interventions for severe proliferative vitreoretinopathy. *Am J Ophthalmol* 2002; 133: 365–372
- ▶ Pastor JC. Proliferative vitreoretinopathy: an overview. *Surv Ophthalmol* 1998; 43: 3–18

Additional Background Reading

- ▶ Diddie KR, Azen SP, Freeman HM et al. Anterior proliferative vitreoretinopathy in the silicone study. Silicone Study Report Number 10. *Ophthalmology* 1996; 103: 1092–1099
- ▶ Lean J, Azen SP, Lopez PF et al. The prognostic utility of the Silicone Study Classification System. Silicone Study Report 9. Silicone Study Group. *Arch Ophthalmol* 1996; 114: 286–292
- ▶ Abrams GW, Azen SP, Barr CC et al. The incidence of corneal abnormalities in the Silicone Study. Silicone Study Report 7. *Arch Ophthalmol* 1995; 113: 764–769
- ▶ Cox MS, Azen SP, Barr CC et al. Macular pucker after successful surgery for proliferative vitreoretinopathy. Silicone Study Report 8. *Ophthalmology* 1995; 102: 1884–1891
- ▶ Hutton WL, Azen SP, Blumenkranz MS et al. The effects of silicone oil removal. Silicone Study Report 6. *Arch Ophthalmol* 1994; 112: 778–785
- ▶ Peyman GA, Greve MD, Millsap CM. Silicone oil vs perfluoropropane gas as a postoperative retinal tamponade. *Arch Ophthalmol* 1994; 112: 728–729; Reply by McCuen BW, Azen SP: 729
- ▶ Chan CK. Reports by the Silicone Study Group. *Arch Ophthalmol* 1993; 111: 428; author reply 429
- ▶ Le Mer Y. Reports by the Silicone Study Group. *Arch Ophthalmol* 1993; 111: 429
- ▶ Barr CC, Lai MY, Lean JS et al. Postoperative intraocular pressure abnormalities in the Silicone Study. Silicone Study Report 4. *Ophthalmology* 1993; 100: 1629–1635
- ▶ Blumenkranz MS, Azen SP, Aaberg T et al. Relaxing retinotomy with silicone oil or long-acting gas in eyes with severe proliferative vitreoretinopathy. Silicone Study Report 5. The Silicone Study Group. *Am J Ophthalmol* 1993; 116: 557–564
- ▶ Azen SP, Boone DC, Barlow W et al. Methods, statistical features, and baseline results of a standardized, multicentered ophthalmologic surgical trial: the Silicone Study. *Control Clin Trials* 1991; 12: 438–455
- ▶ Barlow W, Azen S. The effect of therapeutic treatment cross-overs on the power of clinical trials. The Silicone Study Group. *Control Clin Trials* 1990; 11: 314–326

- ▶ Azen SP, Irvine AR, Davis MD et al. The validity and reliability of photographic documentation of proliferative vitreoretinopathy. *Ophthalmology* 1989; 96: 352–357
- ▶ Boone DC, Lai M, Azen S, Silicone Study Group. Clinical judgment and centralized data management. *Control Clin Trials* 1989: 339
- ▶ Irvine AR. Photographic documentation and grading of PVR, in Freeman HM, Tolentino FI (eds). *Proliferative Vitreoretinopathy*, New York, Springer-Verlag 1989: 105–109
- ▶ Stern WH, Lean JS, Silicone Study Group. Intraocular silicone oil versus gas in the management of proliferative vitreoretinopathy (PVR): A multicenter clinical study, in Freeman HM, Tolentino FI (eds). *Proliferative Vitreoretinopathy*. New York, Springer-Verlag, 1989
- ▶ Glaser BM. Silicone oil for proliferative vitreoretinopathy. Does it help or hinder? *Arch Ophthalmol* 1988; 106: 323–324
- ▶ Lean JS. Changing attitudes in United States to use of intravitreal silicone. *Jpn J Ophthalmol* 1987; 31: 132–137
- ▶ (No authors listed). Proliferative vitreoretinopathy (editorial). The Silicone Study Group. *Am J Ophthalmol* 1985; 99: 593–595
- ▶ Campochiaro PA. The Silicone Study. A small piece of the PVR puzzle is put into place. *Arch Ophthalmol* 1997; 115: 407–408
- ▶ Haller JA, Campochiaro PA. Oil and gas on troubled waters. The proliferative vitreoretinopathy studies. *Arch Ophthalmol* 1992; 110: 768–769
- ▶ choroidal neovascularization. *Invest Ophthalmol Vis Sci* 2001; 42: 447–452
- ▶ Fleckner MR, Hochman MA, Buzney SM et al. Complications of surgery for subfoveal choroidal neovascularization. *Int Ophthalmol Clin* 2000; 40: 201–214
- ▶ Uemura A. [Subretinal surgery for choroidal neovascularization]. *Nippon Ganka Gakkai Zasshi* 2000; 104: 611–620
- ▶ Rao PK, Thomas MA. Update on surgical removal of choroidal neovascularization. *Curr Opin Ophthalmol* 2000; 11: 180–185

Multicenter Trial of Cryotherapy for Retinopathy of Prematurity (CRYO-ROP)

Recommended Reading

- ▶ (No authors listed). Multicenter Trial of Cryotherapy for Retinopathy of Prematurity: ophthalmological outcomes at 10 years. *Arch Ophthalmol* 2001; 119: 1110–1118
- ▶ Repka MX, Palmer EA, Tung B. Involution of retinopathy of prematurity. Cryotherapy for Retinopathy of Prematurity Cooperative Group. *Arch Ophthalmol* 2000; 118: 645–649
- ▶ Saunders RA, Donahue ML, Christmann LM et al. Racial variation in retinopathy of prematurity. The Cryotherapy for Retinopathy of Prematurity Cooperative Group. *Arch Ophthalmol* 1997; 115: 604–608
- ▶ Bartholomew PA, Chao J, Evans JL et al. Acceptance/Use of the Teller acuity card procedure in the clinic. *Am Orthopt J* 1996; 46: 100–106
- ▶ Quinn GE, Dobson V, Barr CC et al. Visual acuity of eyes after vitrectomy for retinopathy of prematurity: follow-up at 5 1/2 years. The Cryotherapy for Retinopathy of Prematurity Cooperative Group. *Ophthalmology* 1996; 103: 595–600
- ▶ (No authors listed). Multicenter trial of cryotherapy for retinopathy of prematurity: natural history ROP: ocular outcome at 5(1/2) years in premature infants with birth weights less than 1251 g. *Arch Ophthalmol* 2002; 120: 595–599

Additional Background Reading

- ▶ (No authors listed). Contrast sensitivity at age 10 years in children who had threshold retinopathy of prematurity. *Arch Ophthalmol* 2001; 119: 1129–1133
- ▶ (No authors listed). Effect of retinal ablative therapy for threshold retinopathy of prematurity: results of Goldmann perimetry at the age of 10 years. *Arch Ophthalmol* 2001; 119: 1120–1125
- ▶ Quinn GE, Dobson V, Siatkowski R et al. Does cryotherapy affect refractive error? Results from treated versus control eyes in the cryotherapy for retinopathy of prematurity trial. *Ophthalmology* 2001; 108: 343–347
- ▶ Msall ME, Phelps DL, DiGaudio KM et al. Severity of neonatal retinopathy of prematurity is predictive of neurodevelopmental functional outcome at age 5.5 years. Behalf of the Cryotherapy for Retinopathy of Prematurity Cooperative Group. *Pediatrics* 2000; 106: 998–1005
- ▶ Dobson V, Quinn GE, Siatkowski RM et al. Agreement between grating acuity at age 1 year and Snellen acuity at age 5.5 years in the preterm child. Cryotherapy for Retinopathy of Prematurity Cooperative Group. *Invest Ophthalmol Vis Sci* 1999; 40: 496–503
- ▶ Harvey EM, Dobson V, Tung B, Quinn GE, Hardy RJ. Interobserver agreement for grating acuity and letter acuity assessment in 1- to 5.5-year-olds with severe retinopathy of prematurity. *Invest Ophthalmol Vis Sci* 1999; 40: 1565–1576

Submacular Surgery Trials (SST)

Recommended Reading

- ▶ Bressler NM, Hawkins BS, Sternberg P Jr., McDonald HR. Are the submacular surgery trials still relevant in an era of photodynamic therapy? *Ophthalmology* 2001; 108: 435–436
- ▶ Grossniklaus HE, Green WR. Histopathologic and ultrastructural findings of surgically excised choroidal neovascularization. Submacular Surgery Trials Research Group. *Arch Ophthalmol* 1998; 116: 745–749

Additional Background Reading

- ▶ Bressler NM, Bressler SB, Hawkins BS et al. Submacular surgery trials randomized pilot trial of laser photocoagulation versus surgery for recurrent choroidal neovascularization secondary to age-related macular degeneration: I. Ophthalmic outcomes submacular surgery trials pilot study report number 1. *Am J Ophthalmol* 2000; 130: 387–407
- ▶ (No authors listed). Submacular surgery trials randomized pilot trial of laser photocoagulation versus surgery for recurrent choroidal neovascularization secondary to age-related macular degeneration: II. Quality of life outcomes submacular surgery trials pilot study report number 2. *Am J Ophthalmol* 2000; 130: 408–418
- ▶ Bressler NM. Submacular surgery. New information, more questions. *Arch Ophthalmol* 1997; 115: 1071–1072
- ▶ Bressler NM. Submacular surgery. Are randomized trials necessary? *Arch Ophthalmol* 1995; 113: 1557–1560
- ▶ Dong LM, Hawkins BS, Marsh MJ. Consistency between visual acuity scores obtained at different test distances: theory vs observations in multiple studies. *Arch Ophthalmol* 2002; 120: 1523–1533
- ▶ Orr PR, Cramer LD, Hawkins BS, Bressler NM. Manifest refraction versus autorefraction for patients with subfoveal

- ▶ Quinn GE, Dobson V, Kivlin J et al. Prevalence of myopia between 3 months and 5 1/2 years in preterm infants with and without retinopathy of prematurity. Cryotherapy for Retinopathy of Prematurity Cooperative Group. *Ophthalmology* 1998; 105: 1292 – 1300
- ▶ Bremer DL, Palmer EA, Fellows RR et al. Strabismus in premature infants in the first year of life. Cryotherapy for Retinopathy of Prematurity Cooperative Group. *Arch Ophthalmol* 1998; 116: 329 – 333
- ▶ Repka MX, Summers CG, Palmer EA et al. The incidence of ophthalmologic interventions in children with birth weights less than 1251 grams. Results through 5 1/2 years. Cryotherapy for Retinopathy of Prematurity Cooperative Group. *Ophthalmology* 1998; 105: 1621 – 1627
- ▶ Hardy RJ, Palmer EA, Schaffer DB et al. Outcome-based management of retinopathy of prematurity. Multicenter Trial of Cryotherapy for Retinopathy of prematurity Cooperative Group. *J Apos* 1997; 1: 46 – 54
- ▶ (No authors listed). Multicenter trial of cryotherapy for retinopathy of prematurity. Snellen visual acuity and structural outcome at 5 1/2 years after randomization. Cryotherapy for Retinopathy of Prematurity Cooperative Group. *Arch Ophthalmol* 1996; 114: 417 – 424
- ▶ Dobson V, Quinn GE, Abramov I et al. Color vision measured with pseudoisochromatic plates at five-and-a-half years in eyes of children from the CRYO-ROP study. *Invest Ophthalmol Vis Sci* 1996; 37: 2467 – 2474
- ▶ Gilbert WS, Quinn GE, Dobson V et al. Partial retinal detachment at 3 months after threshold retinopathy of prematurity. Long-term structural and functional outcome. Multicenter Trial of Cryotherapy for Retinopathy of Prematurity Cooperative Group. *Arch Ophthalmol* 1996; 114: 1085 – 1091
- ▶ Kivlin JD, Biglan AW, Gordon RA et al. Early retinal vessel development and iris vessel dilatation as factors in retinopathy of prematurity. Cryotherapy for Retinopathy of Prematurity (CRYO-ROP) Cooperative Group. *Arch Ophthalmol* 1996; 114: 150 – 154
- ▶ Quinn GE, Dobson V, Hardy RJ et al. Visual fields measured with double-arc perimetry in eyes with threshold retinopathy of prematurity from the cryotherapy for retinopathy of prematurity trial. The CRYO-Retinopathy of Prematurity Cooperative Group. *Ophthalmology* 1996; 103: 1432 – 1437
- ▶ Dobson V, Quinn GE, Saunders RA et al. Grating visual acuity in eyes with retinal residua of retinopathy of prematurity. The Cryotherapy for Retinopathy of Prematurity Cooperative Group. *Arch Ophthalmol* 1995; 113: 1172 – 1177
- ▶ Dobson V, Quinn GE, Tung B, Palmer EA, Reynolds JD. Comparison of recognition and grating acuities in very-low-birth-weight children with and without retinal residua of retinopathy of prematurity. Cryotherapy for Retinopathy of Prematurity Cooperative Group. *Invest Ophthalmol Vis Sci* 1995; 36: 692 – 702
- ▶ Quinn GE, Dobson V, Biglan A et al. Correlation of retinopathy of prematurity in fellow eyes in the cryotherapy for retinopathy of prematurity study. The Cryotherapy for Retinopathy of Prematurity Cooperative Group. *Arch Ophthalmol* 1995; 113: 469 – 473
- ▶ The natural ocular outcome of premature birth and retinopathy. Status at 1 year. Cryotherapy for Retinopathy of Prematurity Cooperative Group. *Arch Ophthalmol* 1994; 112: 903 – 912
- ▶ Dobson V, Quinn GE, Summers CG et al. Effect of acute-phase retinopathy of prematurity on grating acuity development in the very low birth weight infant. The Cryotherapy for Retinopathy of Prematurity Cooperative Group. *Invest Ophthalmol Vis Sci* 1994; 35: 4236 – 4244
- ▶ Multicenter trial of cryotherapy for retinopathy of prematurity. 3 1/2-year outcome – structure and function. Cryotherapy for Retinopathy of Prematurity Cooperative Group. *Arch Ophthalmol* 1993; 111: 339 – 344
- ▶ Evans MS, Wallace PR, Palmer EA. Fundus Photography in small infants. *J Ophthal Photography* 1993; 15: 38 – 39
- ▶ Reynolds J, Dobson V, Quinn GE et al. Prediction of visual function in eyes with mild to moderate posterior pole residua of retinopathy of prematurity. Cryotherapy for Retinopathy of Prematurity Cooperative Group. *Arch Ophthalmol* 1993; 111: 1050 – 1056
- ▶ Schaffer DB, Palmer EA, Plotsky DF et al. Prognostic factors in the natural course of retinopathy of prematurity. The Cryotherapy for Retinopathy of Prematurity Cooperative Group. *Ophthalmology* 1993; 100: 230 – 237
- ▶ Gilbert WS, Dobson V, Quinn GE et al. The correlation of visual function with posterior retinal structure in severe retinopathy of prematurity. Cryotherapy for Retinopathy of Prematurity Cooperative Group. *Arch Ophthalmol* 1992; 110: 625 – 631
- ▶ Quinn GE, Dobson V, Repka MX et al. Development of myopia in infants with birth weights less than 1251 grams. The Cryotherapy for Retinopathy of Prematurity Cooperative Group. *Ophthalmology* 1992; 99: 329 – 340
- ▶ Summers G, Phelps DL, Tung B, Palmer EA. Ocular cosmesis in retinopathy of prematurity. The Cryotherapy for Retinopathy of Prematurity Cooperative Group. *Arch Ophthalmol* 1992; 110: 1092 – 1097
- ▶ Trueb L, Evans J, Hammel A, Bartholomew P, Dobson V. Assessing visual acuity of visually impaired children using the Teller acuity cards. *Am Orthoptic J* 1992; 2: 149 – 154
- ▶ Hardy RJ, Davis BR, Palmer EA, Tung B. Statistical considerations in terminating randomization in the Multicenter Trial of Cryotherapy for Retinopathy of Prematurity. Cryotherapy for Retinopathy of Prematurity Cooperative Group. *Control Clin Trials* 1991; 12: 293 – 303
- ▶ Palmer EA, Flynn JT, Hardy RJ et al. Incidence and early course of retinopathy of prematurity. The Cryotherapy for Retinopathy of Prematurity Cooperative Group. *Ophthalmology* 1991; 98: 1628 – 1640
- ▶ Palmer EA, Hardy RJ, Davis BR et al. Operational aspects of terminating randomization in the Multicenter Trial of Cryotherapy for Retinopathy of Prematurity. Cryotherapy for Retinopathy of Prematurity Cooperative Group. *Control Clin Trials* 1991; 12: 277 – 292
- ▶ Phelps DL, Brown DR, Tung B et al. 28-day survival rates of 6676 neonates with birth weights of 1250 grams or less. *Pediatrics* 1991; 87: 7 – 17
- ▶ Quinn GE, Dobson V, Barr CC et al. Visual acuity in infants after vitrectomy for severe retinopathy of prematurity. *Ophthalmology* 1991; 98: 5 – 13
- ▶ (No authors listed). Multicenter trial of cryotherapy for retinopathy of prematurity. Three-month outcome. Cryotherapy for Retinopathy of Prematurity Cooperative Group. *Arch Ophthalmol* 1990; 108: 195 – 204
- ▶ Dobson V, Quinn GE, Biglan AW et al. Acuity card assessment of visual function in the cryotherapy for retinopathy of pre-

maturity trial. Invest Ophthalmol Vis Sci 1990; 31: 1702 – 1708

- ▶ Watzke RC, Robertson JE Jr., Palmer EA et al. Photographic grading in the retinopathy of prematurity cryotherapy trial. Arch Ophthalmol 1990; 108: 950 – 955
- ▶ Multicenter trial of cryotherapy for retinopathy of prematurity. Preliminary results. Cryotherapy for Retinopathy of Prematurity Cooperative Group. Arch Ophthalmol 1988; 106: 471 – 479
- ▶ Multicenter trial of cryotherapy for retinopathy of prematurity: preliminary results. Cryotherapy for Retinopathy of Prematurity Cooperative Group. Pediatrics 1988; 81: 697 – 706
- ▶ Reynolds JD, Dobson V, Quinn GE et al. Evidence-based screening criteria for retinopathy of prematurity: natural history data from the CRYO-ROP and LIGHT-ROP studies. Arch Ophthalmol 2002; 120: 1470 – 1476
- ▶ Onofrey CB, Feuer WJ, Flynn JT. The outcome of retinopathy of prematurity: screening for retinopathy of prematurity using an outcome predictive program. Ophthalmology 2001; 108: 27 – 34; discussion 34 – 35
- ▶ Clemett R, Darlow B. Results of screening low-birth-weight infants for retinopathy of prematurity. Curr Opin Ophthalmol 1999; 10: 155 – 163
- ▶ (No authors listed). Multicenter trial of cryotherapy for retinopathy of prematurity. One-year outcome – structure and function. Cryotherapy for Retinopathy of Prematurity Cooperative Group. Arch Ophthalmol 1990; 108: 1408 – 1416
- ▶ Palmer EA. Results of U.S. randomized clinical trial of cryotherapy for ROP (CRYO-ROP). Doc Ophthalmol 1990; 74: 245 – 251

Central Vein Occlusion Study (CVOS)

Recommended Reading

- ▶ (No authors listed). Natural history and clinical management of central retinal vein occlusion. The Central Vein Occlusion Study Group. Arch Ophthalmol 1997; 115: 486 – 491
- ▶ (No authors listed). Evaluation of grid pattern photocoagulation for macular edema in central vein occlusion. The Central Vein Occlusion Study Group M report. Ophthalmology 1995; 102: 1425 – 1433
- ▶ (No authors listed). A randomized clinical trial of early pan-retinal photocoagulation for ischemic central vein occlusion. The Central Vein Occlusion Study Group N report. Ophthalmology 1995; 102: 1434 – 1444
- ▶ Fekrat S, Finkelstein D. Current concepts in the management of central retinal vein occlusion. Curr Opin Ophthalmol 1997; 8: 50 – 54

Additional Background Reading

- ▶ Clarkson JG. Central Vein Occlusion Study: photographic protocol and early natural history. Trans Am Ophthalmol Soc 1994; 92: 203 – 213; discussion 213 – 215
- ▶ (No authors listed). Baseline and early natural history report. The Central Vein Occlusion Study. Arch Ophthalmol 1993; 111: 1087 – 1095
- ▶ Soubrane G. Macular edema in retinal vein occlusion: up-date from the central retinal vein occlusion study. Doc Ophthalmol 1999; 97: 279 – 281

Diabetes Control and Complications Trial (DCCT)

Recommended Reading

- ▶ (No authors listed). Lifetime benefits and costs of intensive therapy as practiced in the diabetes control and complications trial. The Diabetes Control and Complications Trial Research Group. Jama 1996; 276: 1409 – 1415
- ▶ (No authors listed). The effect of intensive treatment of diabetes on the development and progression of long-term complications in insulin-dependent diabetes mellitus. The Diabetes Control and Complications Trial Research Group. N Engl J Med 1993; 329: 977 – 986
- ▶ (No authors listed). Progression of retinopathy with intensive versus conventional treatment in the Diabetes Control and Complications Trial. Diabetes Control and Complications Trial Research Group. Ophthalmology 1995; 102: 647 – 661
- ▶ (No authors listed). Early worsening of diabetic retinopathy in the Diabetes Control and Complications Trial. Arch Ophthalmol 1998; 116: 874 – 886 [Erratum appears in Arch Ophthalmol 1998; 116: 1469]
- ▶ (No authors listed). The effect of intensive diabetes treatment on the progression of diabetic retinopathy in insulin-dependent diabetes mellitus. The Diabetes Control and Complications Trial. Arch Ophthalmol 1995; 113: 36 – 51
- ▶ Barr CC. Retinopathy and nephropathy in patients with type 1 diabetes four years after a trial of intensive therapy. The Diabetes Control and Complications Trial/Epidemiology of Diabetes Interventions and Complications Research Group. N Engl J Med 2000; 342: 381 – 389
- ▶ Eastman RC, Javitt JC, Herman WH et al. Model of complications of NIDDM. II. Analysis of the health benefits and cost-effectiveness of treating NIDDM with the goal of normoglycemia. Diabetes Care 1997; 20: 735 – 744
- ▶ Klein R, Klein BE. Relation of glycemic control to diabetic complications and health outcomes. Diabetes Care 1998; 21, Suppl 3: C39 – 43

Additional Background Reading

- ▶ Peterson KA, Smith CK. The DCCT findings and standards of care for diabetes. Am Fam Physician 1995; 52: 1092 – 1098
- ▶ Leiter LA. Use of bioelectrical impedance analysis measurements in patients with diabetes. The Diabetes Control and Complications Trial Research Group. Am J Clin Nutr 1996; 64: S15S – S18S
- ▶ (No authors listed). Epidemiology of severe hypoglycemia in the diabetes control and complications trial. The DCCT Research Group. Am J Med 1991; 90: 450 – 459
- ▶ (No authors listed). Effect of intensive therapy on residual beta-cell function in patients with type 1 diabetes in the diabetes control and complications trial. A randomized, controlled trial. The Diabetes Control and Complications Trial Research Group. Ann Intern Med 1998; 128: 517 – 523
- ▶ (No authors listed). The effect of intensive diabetes therapy on the development and progression of neuropathy. The Diabetes Control and Complications Trial Research Group. Ann Intern Med 1995; 122: 561 – 568
- ▶ (No authors listed). Color photography vs fluorescein angiography in the detection of diabetic retinopathy in the diabetes control and complications trial. The Diabetes Control and Complications Trial Research Group. Arch Ophthalmol 1987; 105: 1344 – 1351
- ▶ Worrall G. Results of the DCCT trial. Implications for managing our patients with diabetes. Can Fam Physician 1994; 40: 1955 – 1960, 1963 – 1965

- ▶ Hoogwerf BJ, Brouhard BH. Glycemic control and complications of diabetes mellitus: practical implications of the Diabetes Control and Complications Trial (DCCT). *Cleve Clin J Med* 1994; 61: 34–37; quiz 80–82
- ▶ (No authors listed). Feasibility of centralized measurements of glycated hemoglobin in the Diabetes Control and Complications Trial: a multicenter study. The DCCT Research Group. *Clin Chem* 1987; 33: 2267–2271
- ▶ (No authors listed). Implementation of a multicomponent process to obtain informed consent in the Diabetes Control and Complications Trial. The DCCT Research Group. *Control Clin Trials* 1989; 10: 83–96
- ▶ (No authors listed). Clustering of long-term complications in families with diabetes in the diabetes control and complications trial. The Diabetes Control and Complications Trial Research Group. *Diabetes* 1997; 46: 1829–1839
- ▶ (No authors listed). Factors in development of diabetic neuropathy. Baseline analysis of neuropathy in feasibility phase of Diabetes Control and Complications Trial (DCCT). The DCCT Research Group. *Diabetes* 1988; 37: 476–481
- ▶ (No authors listed). Hypoglycemia in the Diabetes Control and Complications Trial. The Diabetes Control and Complications Trial Research Group. *Diabetes* 1997; 46: 271–286
- ▶ Monnier VM, Bautista O, Kenny D et al. Skin collagen glycation, glycoxidation, and crosslinking are lower in subjects with long-term intensive versus conventional therapy of type 1 diabetes: relevance of glycated collagen products versus HbA1c as markers of diabetic complications. DCCT Skin Collagen Ancillary Study Group. *Diabetes Control and Complications Trial*. *Diabetes* 1999; 48: 870–880
- ▶ (No authors listed). The Diabetes Control and Complications Trial (DCCT). Design and methodologic considerations for the feasibility phase. The DCCT Research Group. *Diabetes* 1986; 35: 530–545
- ▶ Gautier JF, Beressi JP, Leblanc H, Vexiau P, Passa P. Are the implications of the Diabetes Control and Complications Trial (DCCT) feasible in daily clinical practice? *Diabetes Metab* 1996; 22: 415–419
- ▶ McCulloch DK, Glasgow RE, Hampson SE, Wagner E. A systematic approach to diabetes management in the post-DCCT era. *Diabetes Care* 1994; 17: 765–769
- ▶ Moses RG, Rodgers DV, Griffiths RD. Clinic variations hold important clues to the understanding and implementation of the DCCT results. *Diabetes Care* 1996; 19: 178–180
- ▶ Dagogo-Jack S. DCCT results and diabetes care in developing countries. *Diabetes Care* 1995; 18: 416–417
- ▶ (No authors listed). Diabetes Control and Complications Trial (DCCT): results of feasibility study. The DCCT Research Group. *Diabetes Care* 1987; 10: 1–19
- ▶ (No authors listed). Diabetes Control and Complications Trial (DCCT). Update. DCCT Research Group. *Diabetes Care* 1990; 13: 427–433
- ▶ (No authors listed). Effect of pregnancy on microvascular complications in the diabetes control and complications trial. The Diabetes Control and Complications Trial Research Group. *Diabetes Care* 2000; 23: 1084–1091
- ▶ Orchard TJ. From diagnosis and classification to complications and therapy. DCCT. Part II? Diabetes Control and Complications Trial. *Diabetes Care* 1994; 17: 326–338
- ▶ Thompson CJ, Cummings JF, Chalmers J, Gould C, Newton RW. How have patients reacted to the implications of the DCCT? *Diabetes Care* 1996; 19: 876–879
- ▶ Rubin RR, Peyrot M. Implications of the DCCT. Looking beyond tight control. *Diabetes Care* 1994; 17: 235–236
- ▶ (No authors listed). Lipid and lipoprotein levels in patients with IDDM diabetes control and complication. Trial experience. The DCCT Research Group. *Diabetes Care* 1992; 15: 886–894
- ▶ (No authors listed). Reliability and validity of a diabetes quality-of-life measure for the diabetes control and complications trial (DCCT). The DCCT Research Group. *Diabetes Care* 1988; 11: 725–732
- ▶ Harris MI, Eastman RC, Siebert C. The DCCT and medical care for diabetes in the U.S. *Diabetes Care* 1994; 17: 761–764
- ▶ (No authors listed). Weight gain associated with intensive therapy in the diabetes control and complications trial. The DCCT Research Group. *Diabetes Care* 1988; 11: 567–573
- ▶ (No authors listed). AADE position statement: Diabetes Control and Complications Trial (DCCT). *Diabetes Educ* 1994; 20: 106, 108
- ▶ Ahern JA, Kruger DF, Gatcomb PM, Petit WA Jr., Tamborlane WV. The diabetes control and complications trial (DCCT): the trial coordinator perspective. Report by the DCCT Research Group. *Diabetes Educ* 1989; 15: 236–241
- ▶ Ahern J, Grove N, Strand T et al. The impact of the Trial Coordinator in the Diabetes Control and Complications Trial (DCCT). The DCCT Research Group. *Diabetes Educ* 1993; 19: 509–512
- ▶ Ahern JA, Ramchandani N, Cooper J et al. Using a primary nurse manager to implement DCCT recommendations in a large pediatric program. *Diabetes Educ* 2000; 26: 990–994
- ▶ Molyneaux LM, Constantino MI, McGill M, Zilkens R, Yue DK. Better glycaemic control and risk reduction of diabetic complications in Type 2 diabetes: comparison with the DCCT. *Diabetes Res Clin Pract* 1998; 42: 77–83
- ▶ (No authors listed). Implementing the lessons of DCCT. Report of a national workshop under the auspices of the British Diabetic Association. *Diabet Med* 1994; 11: 220–228
- ▶ Gibb I, Parnham AJ, Lord C et al. Standardization of glycated haemoglobin assays throughout the Northern region of England: a pilot study. *Diabet Med* 1997; 14: 584–588
- ▶ (No authors listed). The effect of intensive diabetes therapy on measures of autonomic nervous system function in the Diabetes Control and Complications Trial (DCCT). *Diabetologia* 1998; 41: 416–423
- ▶ Zinman B. Translating the Diabetes Control and Complications Trial (DCCT) into clinical practice: overcoming the barriers. *Diabetologia* 1997; 40 Suppl 2: S88–90
- ▶ Szucs TD, Smala AM, Fischer T. [Costs of intensive insulin therapy in type 1 diabetes mellitus. Experiences from the DCCT study]. *Fortschr Med* 1998; 116: 34–38. German
- ▶ Leiter LA, Lukaski HC, Kenny DJ et al. The use of bioelectrical impedance analysis (BIA) to estimate body composition in the Diabetes Control and Complications Trial (DCCT). *Int J Obes Relat Metab Disord* 1994; 18: 829–835
- ▶ Purnell JQ, Hokanson JE, Marcovina SM et al. Effect of excessive weight gain with intensive therapy of type 1 diabetes on lipid levels and blood pressure: results from the DCCT. *Diabetes Control and Complications Trial*. *Jama* 1998; 280: 140–146 [Erratum appears in *JAMA* 1998; 280: 1841]
- ▶ (No authors listed). A screening algorithm to identify clinically significant changes in neuropsychological functions in the Diabetes Control and Complications Trial. DCCT Research Group. *J Clin Exp Neuropsychol* 1994; 16: 303–316

- ▶ (No authors listed). Effects of age, duration and treatment of insulin-dependent diabetes mellitus on residual beta-cell function: observations during eligibility testing for the Diabetes Control and Complications Trial (DCCT). The DCCT Research Group. *J Clin Endocrinol Metab* 1987; 65: 30–36
- ▶ White NH, Cleary PA, Dahms W et al. Beneficial effects of intensive therapy of diabetes during adolescence: outcomes after the conclusion of the Diabetes Control and Complications Trial (DCCT). *J Pediatr* 2001; 139: 804–812
- ▶ (No authors listed). Effect of intensive diabetes treatment on the development and progression of long-term complications in adolescents with insulin-dependent diabetes mellitus: Diabetes Control and Complications Trial. Diabetes Control and Complications Trial Research Group. *J Pediatr* 1994; 125: 177–188
- ▶ Moses R, Rodgers D, Griffiths R. Diabetic control and hypoglycaemia in the Illawarra area of NSW, Australia: a comparison with the DCCT. *J Qual Clin Pract* 1995; 15: 89–97
- ▶ Delahanty L, Simkins SW, Camelon K. Expanded role of the dietitian in the Diabetes Control and Complications Trial: implications for clinical practice. The DCCT Research Group. *J Am Diet Assoc* 1993; 93: 758–764, 767
- ▶ Anderson EJ, Richardson M, Castle G et al. Nutrition interventions for intensive therapy in the Diabetes Control and Complications Trial. The DCCT Research Group. *J Am Diet Assoc* 1993; 93: 768–772
- ▶ Schmidt LE, Cox MS, Buzzard IM, Cleary PA. Reproducibility of a comprehensive diet history in the Diabetes Control and Complications Trial. The DCCT Research Group. *J Am Diet Assoc* 1994; 94: 1392–1397
- ▶ Levey AS, Greene T, Schluchter MD et al. Glomerular filtration rate measurements in clinical trials. Modification of Diet in Renal Disease Study Group and the Diabetes Control and Complications Trial Research Group. *J Am Soc Nephrol* 1993; 4: 1159–1171
- ▶ Molitch ME, Steffes MW, Cleary PA, Nathan DM. Baseline analysis of renal function in the Diabetes Control and Complications Trial. The Diabetes Control and Complications Trial Research Group [corrected]. *Kidney Int* 1993; 43: 668–674
- ▶ (No authors listed). Effect of intensive therapy on the development and progression of diabetic nephropathy in the Diabetes Control and Complications Trial. The Diabetes Control and Complications (DCCT) Research Group. *Kidney Int* 1995; 47: 1703–1720
- ▶ Covic AM, Schelling JR, Constantiner M, Iyengar SK, Sedor JR. Serum C-peptide concentrations poorly phenotype type 2 diabetic end-stage renal disease patients. *Kidney Int* 2000; 58: 1742–1750
- ▶ Chrisholm DJ. The Diabetes Control and Complications Trial (DCCT). A milestone in diabetes management. *Med J Aust* 1993; 159: 721–723
- ▶ Nosadini R, Abaterusso C, Dalla Vestra M et al. Efficacy of antihypertensive therapy in decreasing renal and cardiovascular complications in diabetes mellitus. *Nephrol Dial Transplant* 1998; 13 Suppl 8: 44–48
- ▶ Rapaport R, Sills IN. Implications of the DCCT for children and adolescents with IDDM. *N J Med* 1994; 91: 227–228
- ▶ (No authors listed). Effect of intensive diabetes management on macrovascular events and risk factors in the Diabetes Control and Complications Trial. *Am J Cardiol* 1995; 75: 894–903
- ▶ Schwartz R, Teramo KA. Pregnancy outcome, Diabetes Control and Complications Trial, and intensive glycemic control. *Am J Obstet Gynecol* 1998; 178: 416–417
- ▶ (No authors listed). Pregnancy outcomes in the Diabetes Control and Complications Trial. *Am J Obstet Gynecol* 1996; 174: 1343–1353
- ▶ (No authors listed). Effect of intensive therapy on the microvascular complications of type 1 diabetes mellitus. *Jama* 2002; 287: 2563–2569
- ▶ (No authors listed). Effects of intensive diabetes therapy on neuropsychological function in adults in the Diabetes Control and Complications Trial. *Ann Intern Med* 1996; 124: 379–388
- ▶ Brink SJ. How to apply the experience from the diabetes control and complications trial to children and adolescents? *Ann Med* 1997; 29: 425–438
- ▶ (No authors listed). Effect of intensive diabetes treatment on nerve conduction in the Diabetes Control and Complications Trial. *Ann Neurol* 1995; 38: 869–880
- ▶ Carlisle BA. The implications of diabetes control and complications trial for the pharmacy profession. *Ann Pharmacother* 1996; 30: 294–295
- ▶ Klein R, Moss S. A comparison of the study populations in the Diabetes Control and Complications Trial and the Wisconsin Epidemiologic Study of Diabetic Retinopathy. *Arch Intern Med* 1995; 155: 745–754
- ▶ Duron F. Intensive insulin therapy in insulin-dependent diabetes mellitus, the results of the diabetes control and complications trial. *Biomed Pharmacother* 1995; 49: 278–282
- ▶ Newman RJ. A method to implement the recommendations of the diabetes control and complications trial in a busy pediatric outpatient practice. *Pediatr Ann* 1999; 28: 594–598
- ▶ Fenton CL, Clemons PM, Francis GL. How do the results of the diabetes control and complications trial relate to the practice of pediatrics: who should have intensive management? *Pediatr Ann* 1999; 28: 600–604
- ▶ Malone JL. Lessons for pediatricians from the diabetes control and complications trial. *Pediatr Ann* 1994; 23: 295–299
- ▶ Tamborlane WV, Ahern J. Implications and results of the Diabetes Control and Complications Trial. *Pediatr Clin North Am* 1997; 44: 285–300
- ▶ Vinik AI, Richardson DW. Implications of the diabetes control and complications trial for persons with non-insulin-dependent diabetes mellitus. *South Med J* 1997; 90: 268–282
- ▶ Saudek CD. Non-ophthalmologic findings of the Diabetes Control and Complications Trial. *Surv Ophthalmol* 1995; 40: 157–162
- ▶ Nuttall FQ. Comparison of percent total GHb with percent HbA1c in people with and without known diabetes. *Diabetes Care* 1998; 21: 1475–1480
- ▶ Ruggiero L, Glasgow R, Dryfoos JM et al. Diabetes self-management. Self-reported recommendations and patterns in a large population. *Diabetes Care* 1997; 20: 568–576
- ▶ Levin SR, Coburn JW, Abairra C et al. Effect of intensive glycemic control on microalbuminuria in type 2 diabetes. Veterans Affairs Cooperative Study on Glycemic Control and Complications in Type 2 Diabetes Feasibility Trial Investigators. *Diabetes Care* 2000; 23: 1478–1485
- ▶ Rosilio M, Cotton JB, Wieliczko MC et al. Factors associated with glycemic control. A cross-sectional nationwide study in 2,579 French children with type 1 diabetes. The French Pediatric Diabetes Group. *Diabetes Care* 1998; 21: 1146–1153

- ▶ (No authors listed). Factors influencing glycemic control in young people with type 1 diabetes in Scotland: a population-based study (DIABAUD2). *Diabetes Care* 2001; 24: 239–244
- ▶ Yokoyama H, Okudaira M, Otani T et al. High incidence of diabetic nephropathy in early-onset Japanese NIDDM patients. Risk analysis. *Diabetes Care* 1998; 21: 1080–1085
- ▶ Dunn FL, Nathan DM, Scavini M, Selam JL, Wingrove TG. Long-term therapy of IDDM with an implantable insulin pump. The Implantable Insulin Pump Trial Study Group. *Diabetes Care* 1997; 20: 59–63
- ▶ Miller CD, Phillips LS, Tate MK et al. Meeting American Diabetes Association guidelines in endocrinologist practice. *Diabetes Care* 2000; 23: 444–448
- ▶ Eastman RC, Javitt JC, Herman WH et al. Model of complications of NIDDM. I. Model construction and assumptions. *Diabetes Care* 1997; 20: 725–734
- ▶ Keen H. The Diabetes Control and Complications Trial (DCCT). *Health Trends* 1994; 26: 41–43
- ▶ Tercyak KP Jr., Johnson SB, Kirkpatrick KA, Silverstein JH. Offering a randomized trial of intensive therapy for IDDM to adolescents. Reasons for refusal, patient characteristics, and recruiter effects. *Diabetes Care* 1998; 21: 213–215
- ▶ Glasgow RE, Ruggiero L, Eakin EG, Dryfoos J, Chobanian L. Quality of life and associated characteristics in a large national sample of adults with diabetes. *Diabetes Care* 1997; 20: 562–567

Diabetic Retinopathy Study (DRS)

Recommended Reading

- ▶ (No authors listed). Indications for photocoagulation treatment of diabetic retinopathy: Diabetic Retinopathy Study Report no. 14. The Diabetic Retinopathy Study Research Group. *Int Ophthalmol Clin* 1987; 27: 239–253
- ▶ Kaufman SC, Ferris FL 3rd, Seigel DG, Davis MD, DeMets DL. Factors associated with visual outcome after photocoagulation for diabetic retinopathy. Diabetic Retinopathy Study Report #13. *Invest Ophthalmol Vis Sci* 1989; 30: 23–28
- ▶ Ferris FL 3rd, Podgor MJ, Davis MD. Macular edema in Diabetic Retinopathy Study patients. Diabetic Retinopathy Study Report Number 12. *Ophthalmology* 1987; 94: 754–760
- ▶ Rand LI, Prud'homme GJ, Ederer F, Canner PL. Factors influencing the development of visual loss in advanced diabetic retinopathy. Diabetic Retinopathy Study (DRS) Report No. 10. *Invest Ophthalmol Vis Sci* 1985; 26: 983–991

Additional Background Reading

- ▶ Kaufman SC, Ferris FL 3rd, Swartz M. Intraocular pressure following panretinal photocoagulation for diabetic retinopathy. Diabetic Retinopathy Report No. 11. *Arch Ophthalmol* 1987; 105: 807–809
- ▶ Ederer F, Podgor MJ. Assessing possible late treatment effects in stopping a clinical trial early: a case study. Diabetic Retinopathy Study report No. 9. *Control Clin Trials* 1984; 5: 373–381
- ▶ (No authors listed). Diabetic retinopathy study. Report Number 6. Design, methods, and baseline results. Report Number 7. A modification of the Airlie House classification of diabetic retinopathy. Prepared by the Diabetic Retinopathy. *Invest Ophthalmol Vis Sci* 1981; 21: 1–226
- ▶ Photocoagulation treatment of proliferative diabetic retinopathy: relationship of adverse treatment effects to retinopa-

thy severity. Diabetic retinopathy study report no. 5. *Dev Ophthalmol* 1981; 2: 248–261

- ▶ (No authors listed). Photocoagulation treatment of proliferative diabetic retinopathy. Clinical application of Diabetic Retinopathy Study (DRS) findings, DRS Report Number 8. The Diabetic Retinopathy Study Research Group. *Ophthalmology* 1981; 88: 583–600
- ▶ (No authors listed). Four risk factors for severe visual loss in diabetic retinopathy. The third report from the Diabetic Retinopathy Study. The Diabetic Retinopathy Study Research Group. *Arch Ophthalmol* 1979; 97: 654–655
- ▶ Preliminary report on effects of photocoagulation therapy. The Diabetic Retinopathy Study Research Group. *Am J Ophthalmol* 1976; 81: 383–396

Early Treatment Diabetic Retinopathy Study (ETDRS)

Recommended Reading

- ▶ Fong DS, Ferris FL 3rd, Davis MD, Chew EY. Causes of severe visual loss in the early treatment diabetic retinopathy study: ETDRS report no. 24. Early Treatment Diabetic Retinopathy Study Research Group. *Am J Ophthalmol* 1999; 127: 137–141
- ▶ Chew EY, Klein ML, Murphy RP, Remaley NA, Ferris FL 3rd. Effects of aspirin on vitreous/preretinal hemorrhage in patients with diabetes mellitus. Early Treatment Diabetic Retinopathy Study report no. 20. *Arch Ophthalmol* 1995; 113: 52–55
- ▶ (No authors listed). Focal photocoagulation treatment of diabetic macular edema. Relationship of treatment effect to fluorescein angiographic and other retinal characteristics at baseline: ETDRS report no. 19. Early Treatment Diabetic Retinopathy Study Research Group. *Arch Ophthalmol* 1995; 113: 1144–1155
- ▶ (No authors listed). Early photocoagulation for diabetic retinopathy. ETDRS report number 9. Early Treatment Diabetic Retinopathy Study Research Group. *Ophthalmology* 1991; 98: 766–785
- ▶ (No authors listed). Grading diabetic retinopathy from stereoscopic color fundus photographs – an extension of the modified Airlie House classification. ETDRS report number 10. Early Treatment Diabetic Retinopathy Study Research Group. *Ophthalmology* 1991; 98: 786–806
- ▶ (No authors listed). Classification of diabetic retinopathy from fluorescein angiograms. ETDRS report number 11. Early Treatment Diabetic Retinopathy Study Research Group. *Ophthalmology* 1991; 98: 807–822
- ▶ (No authors listed). Fundus photographic risk factors for progression of diabetic retinopathy. ETDRS report number 12. Early Treatment Diabetic Retinopathy Study Research Group. *Ophthalmology* 1991 May; 98(5 Suppl): 823–33
- ▶ (No authors listed). Treatment techniques and clinical guidelines for photocoagulation of diabetic macular edema. Early Treatment Diabetic Retinopathy Study Report Number 2. Early Treatment Diabetic Retinopathy Study Research Group. *Ophthalmology* 1987; 94: 761–774
- ▶ (No authors listed). Techniques for scatter and local photocoagulation treatment of diabetic retinopathy: Early Treatment Diabetic Retinopathy Study report no. 3. The Early Treatment Diabetic Retinopathy Study Research Group. *Int Ophthalmol Clin* 1987; 27: 254–264
- ▶ Fong DS, Segal PP, Myers F et al. Subretinal fibrosis in diabetic macular edema. ETDRS report 23. Early Treatment Diabetic

Retinopathy Study Research Group. *Arch Ophthalmol* 1997; 115: 873–877

Additional Background Reading

- ▶ Fong DS, Barton FB, Bresnick GH. Impaired color vision associated with diabetic retinopathy: Early Treatment Diabetic Retinopathy Study Report No. 15. *Am J Ophthalmol* 1999; 128: 612–617
- ▶ Chew EY, Klein ML, Ferris FL 3rd et al. Association of elevated serum lipid levels with retinal hard exudate in diabetic retinopathy. Early Treatment Diabetic Retinopathy Study (ETDRS) Report 22. *Arch Ophthalmol* 1996; 114: 1079–1084
- ▶ Ferris F. Early photocoagulation in patients with either type I or type II diabetes. *Trans Am Ophthalmol Soc* 1996; 94: 505–537
- ▶ Ferris FL 3rd, Chew EY, Hoogwerf BJ. Serum lipids and diabetic retinopathy. Early Treatment Diabetic Retinopathy Study Research Group. *Diabetes Care* 1996; 19: 1291–1293
- ▶ Braun CI, Benson WE, Remaley NA, Chew EY, Ferris FL 3rd. Accommodative amplitudes in the Early Treatment Diabetic Retinopathy Study. *Retina* 1995; 15: 275–281
- ▶ Prior MJ, Prout T, Miller D, Ewart R, Kumar D. C-peptide and the classification of diabetes mellitus patients in the Early Treatment Diabetic Retinopathy Study. Report number 6. The ETDRS Research Group. *Ann Epidemiol* 1993; 3: 9–17
- ▶ (No authors listed). Aspirin effects on mortality and morbidity in patients with diabetes mellitus. Early Treatment Diabetic Retinopathy Study report 14. ETDRS Investigators. *Jama* 1992; 268: 1292–1300
- ▶ Chew EY, Williams GA, Burton TC et al. Aspirin effects on the development of cataracts in patients with diabetes mellitus. Early treatment diabetic retinopathy study report 16. *Arch Ophthalmol* 1992; 110: 339–342
- ▶ Flynn HW Jr., Chew EY, Simons BD et al. Pars plana vitrectomy in the Early Treatment Diabetic Retinopathy Study. ETDRS report number 17. The Early Treatment Diabetic Retinopathy Study Research Group. *Ophthalmology* 1992; 99: 1351–1357
- ▶ (No authors listed). Early Treatment Diabetic Retinopathy Study design and baseline patient characteristics. ETDRS report number 7. *Ophthalmology* 1991; 98: 741–756
- ▶ (No authors listed). Effects of aspirin treatment on diabetic retinopathy. ETDRS report number 8. Early Treatment Diabetic Retinopathy Study Research Group. *Ophthalmology* 1991; 98: 757–765
- ▶ (No authors listed). Fluorescein angiographic risk factors for progression of diabetic retinopathy. ETDRS report number 13. Early Treatment Diabetic Retinopathy Study Research Group. *Ophthalmology* 1991; 98: 834–840
- ▶ Kinyoun J, Barton F, Fisher M et al. Detection of diabetic macular edema. Ophthalmoscopy versus photography – Early Treatment Diabetic Retinopathy Study Report Number 5. The ETDRS Research Group. *Ophthalmology* 1989; 96: 746–750; discussion 750–751
- ▶ (No authors listed). Photocoagulation for diabetic macular edema: Early Treatment Diabetic Retinopathy Study Report no. 4. The Early Treatment Diabetic Retinopathy Study Research Group. *Int Ophthalmol Clin* 1987; 27: 265–272
- ▶ (No authors listed). Photocoagulation for diabetic macular edema. Early Treatment Diabetic Retinopathy Study report number 1. Early Treatment Diabetic Retinopathy Study research group. *Arch Ophthalmol* 1985; 103: 1796–1806
- ▶ Ferris FL 3rd. Photocoagulation for diabetic retinopathy. Early Treatment Diabetic Retinopathy Study Research Group. *Jama* 1991; 266: 1263–1265
- ▶ (No authors listed). Case reports to accompany Early Treatment Diabetic Retinopathy Study Reports 3 and 4. The Early Treatment Diabetic Retinopathy Study Research Group. *Int Ophthalmol Clin* 1987; 27: 273–333
- ▶ (No authors listed). Photocoagulation therapy for diabetic eye disease. Early Treatment Diabetic Retinopathy Study Research Group. *Jama* 1985; 254: 3086

UVEITIS

Randomized Trial of Acetazolamide for Uveitis-Associated Cystoid Macular Edema

Recommended Reading

- ▶ Jabs DA, Mudun A, Dunn JP, Marsh MJ. Episcleritis and scleritis: clinical features and treatment results. *Am J Ophthalmol* 2000; 130: 469–476
- ▶ Jabs DA, Rosenbaum JT, Foster CS et al. Guidelines for the use of immunosuppressive drugs in patients with ocular inflammatory disorders: recommendations of an expert panel. *Am J Ophthalmol* 2000; 130: 492–513
- ▶ Nguyen QD, Kempen JH, Bolton SG, Dunn JP, Jabs DA. Immune recovery uveitis in patients with AIDS and cytomegalovirus retinitis after highly active antiretroviral therapy. *Am J Ophthalmol* 2000; 129: 634–639
- ▶ Tay-Kearney ML, Schwam BL, Lowder C et al. Clinical features and associated systemic diseases of HLA-B27 uveitis. *Am J Ophthalmol* 1996; 121: 47–56
- ▶ Whitcup SM, Csaky KG, Podgor MJ et al. A randomized, masked, cross-over trial of acetazolamide for cystoid macular edema in patients with uveitis. *Ophthalmology* 1996; 103: 1054–1062; discussion 1062–1063
- ▶ Robinson MR, Reed G, Csaky KG, Polis MA, Whitcup SM. Immune-recovery uveitis in patients with cytomegalovirus retinitis taking highly active antiretroviral therapy. *Am J Ophthalmol* 2000; 130: 49–56
- ▶ Lertsumitkul S, Whitcup SM, Nussenblatt RB, Chan CC. Subretinal fibrosis and choroidal neovascularization in Vogt-Koyanagi-Harada syndrome. *Graefes Arch Clin Exp Ophthalmol* 1999; 237: 1039–1045
- ▶ Chan CC, Roberge RG, Whitcup SM, Nussenblatt RB. 32 cases of sympathetic ophthalmia. A retrospective study at the National Eye Institute, Bethesda, Md., from 1982 to 1992. *Arch Ophthalmol* 1995; 113: 597–600. [erratum appears in *Arch Ophthalmol* 1995; 113: 1507]
- ▶ Nussenblatt RB. Clinical studies of Vogt-Koyanagi-Harada's disease at the National Eye Institute, NIH, USA. *Jpn J Ophthalmol* 1988; 32: 330–333

ONCOLOGY

Collaborative Ocular Melanoma Study (COMS)

Recommended Reading

- ▶ (No authors listed). Mortality in patients with small choroidal melanoma. COMS report no. 4. The Collaborative Ocular Melanoma Study Group. *Arch Ophthalmol* 1997; 115: 886–893
- ▶ (No authors listed). Factors predictive of growth and treatment of small choroidal melanoma: COMS Report No. 5. The

Collaborative Ocular Melanoma Study Group. *Arch Ophthalmol* 1997; 115: 1537–1544

- ▶ (No authors listed). Assessment of metastatic disease status at death in 435 patients with large choroidal melanoma in the Collaborative Ocular Melanoma Study (COMS): COMS report no. 15. *Arch Ophthalmol* 2001; 119: 670–676
- ▶ Melia BM, Abramson DH, Albert DM et al. Collaborative ocular melanoma study (COMS) randomized trial of I-125 brachytherapy for medium choroidal melanoma. I. Visual acuity after 3 years COMS report no. 16. *Ophthalmology* 2001; 108: 348–366
- ▶ Diener-West M, Earle JD, Fine SL et al. The COMS randomized trial of iodine 125 brachytherapy for choroidal melanoma, III: initial mortality findings. COMS Report No. 18. *Arch Ophthalmol* 2001; 119: 969–982
- ▶ Jampol LM, Moy CS, Murray TG et al. The COMS randomized trial of iodine 125 brachytherapy for choroidal melanoma: IV. Local treatment failure and enucleation in the first 5 years after brachytherapy. COMS report no. 19. *Ophthalmology* 2002; 109: 2197–2206

Additional Background Reading

- ▶ Straatsma BR, Fine SL, Earle JD et al. Enucleation versus plaque irradiation for choroidal melanoma. *Ophthalmology* 1988; 95: 1000–1004
- ▶ (No authors listed). Accuracy of diagnosis of choroidal melanomas in the Collaborative Ocular Melanoma Study. COMS report no. 1. *Arch Ophthalmol* 1990; 108: 1268–1273
- ▶ (No authors listed). Design and methods of a clinical trial for a rare condition: the Collaborative Ocular Melanoma Study. COMS Report No. 3. *Control Clin Trials* 1993; 14: 362–391
- ▶ Wells CG, Bradford RH, Fish GE, Straatsma BR, Hawkins BS. Choroidal melanomas in American Indians. COMS Group. Collaborative Ocular Melanoma Study. *Arch Ophthalmol* 1996; 114: 1017–1018
- ▶ (No authors listed). Histopathologic characteristics of uveal melanomas in eyes enucleated from the Collaborative Ocular Melanoma Study. COMS report no. 6. *Am J Ophthalmol* 1998; 125: 745–766
- ▶ (No authors listed). Sociodemographic and clinical predictors of participation in two randomized trials: findings from the Collaborative Ocular Melanoma Study COMS report no. 7. *Control Clin Trials* 2001; 22: 526–537
- ▶ Grossniklaus HE, Albert DM, Green WR, Conway BP, Hovland KR. Clear cell differentiation in choroidal melanoma. COMS report no. 8. Collaborative Ocular Melanoma Study Group. *Arch Ophthalmol* 1997; 115: 894–898
- ▶ (No authors listed). The Collaborative Ocular Melanoma Study (COMS) randomized trial of pre-enucleation radiation of large choroidal melanoma I: characteristics of patients enrolled and not enrolled. COMS report no. 9. *Am J Ophthalmol* 1998; 125: 767–778
- ▶ The Collaborative Ocular Melanoma Study (COMS) randomized trial of pre-enucleation radiation of large choroidal melanoma II: initial mortality findings. COMS report no. 10. *Am J Ophthalmol* 1998; 125: 779–796
- ▶ (No authors listed). The Collaborative Ocular Melanoma Study (COMS) randomized trial of pre-enucleation radiation of large choroidal melanoma III: local complications and observations following enucleation COMS report no. 11. *Am J Ophthalmol* 1998; 126: 362–372
- ▶ (No authors listed). Echography (ultrasound) procedures for the Collaborative Ocular Melanoma Study (COMS), Report no. 12, Part I. *J Ophthalmic Nurs Technol* 1999; 18: 143–149
- ▶ (No authors listed). Echography (Ultrasound) Procedures for the Collaborative Ocular Melanoma Study (COMS), Report no. 12, Part II. *J Ophthalmic Nurs Technol* 1999; 18: 219–232
- ▶ Byrne SF, Marsh MJ, Boldt HC et al. Consistency of observations from echograms made centrally in the Collaborative Ocular Melanoma Study COMS Report No. 13. *Ophthalmic Epidemiol* 2002; 9: 11–27
- ▶ Moy CS, Albert DM, Diener-West M et al. Cause-specific mortality coding. methods in the collaborative ocular melanoma study coms report no. 14. *Control Clin Trials* 2001; 22: 248–262
- ▶ Diener-West M, Earle JD, Fine SL et al. The COMS randomized trial of iodine 125 brachytherapy for choroidal melanoma, II: characteristics of patients enrolled and not enrolled. COMS Report No. 17. *Arch Ophthalmol* 2001; 119: 951–965
- ▶ (No authors listed). Quality of life assessment in the collaborative ocular melanoma study: design and methods. COMS-QOLS Report No. 1. COMS Quality of Life Study Group. *Ophthalmic Epidemiol* 1999; 6: 5–17
- ▶ Melia BM, Moy CS, McCaffrey L. Quality of life in patients with choroidal melanoma: a pilot study. *Ophthalmic Epidemiol* 1999; 6: 19–28
- ▶ Fine SL. How should we manage a patient with uveal melanoma? *Arch Ophthalmol* 1985; 103: 910–911
- ▶ Fine SL. Do I take the eye out or leave it in? [Editorial]. *Arch Ophthalmol* 1986; 104: 653–654. Letter and response: *Arch Ophthalmol* 1986; 1746–1747
- ▶ Fine SL. The collaborative Ocular Melanoma Study. Research to Prevent Blindness, Inc. Science Writers Seminar, 1987
- ▶ Earle J, Kline RW, Robertson DM. Selection of iodine 125 for the Collaborative Ocular Melanoma Study. *Arch Ophthalmol* 1987; 105: 763–764
- ▶ Robertson DM, Earle JD, Kline RW. Brachytherapy for choroidal melanoma (Chapter 45). In: Ryan SJ (ed): *Retina* 3rd Edition. Mosby Inc., St. Louis, 2001, pp. 739–52
- ▶ Hawkins BS, Schachat AP. Collaborative Ocular Melanoma Study (Chapter 47). In: Ryan SJ (ed): *Retina* 3rd Edition. Mosby Inc., St. Louis, 2001, pp. 798–806
- ▶ Robertson DM. A rationale for comparing radiation to enucleation in the management of choroidal melanoma. *Am J Ophthalmol* 1989; 108: 448–451
- ▶ Collaborative Ocular Melanoma Study Steering Committee: Response to Char et al: “Failure of preenucleation radiation to decrease uveal melanoma mortality” [Letter]. *Am J Ophthalmol* 1989; 107: 440–441
- ▶ Schachat AP, Markowitz JA, Hawkins BS, Fine SL. Nonocular cancers in patients with choroidal melanoma. *Ophthalmology* 1990; 97: 837–838
- ▶ Park WL. The Collaborative Ocular Melanoma Study. *J Am Optom Assoc* 1992; 63: 609–610
- ▶ Ruiz RS, Diaz D. Collaborative Ocular Melanoma Study: Iodine-125 plaque therapy. *Cancer Bull* 1992; 44: 360–365
- ▶ Collaborative Ocular Melanoma Study Group. Complications of enucleation surgery. COMS Report No. 2. In: Franklin RM (ed): *Proceedings of the Symposium on Retina and Vitreous*. New Orleans Academy of Ophthalmology. Kugler Publications, New York, 1993, pp. 181–90
- ▶ Fine SL. Choroidal melanoma. A practical approach for the 1990's. In: Franklin RM (ed): *Proceedings of the Symposium*

- on Retina and Vitreous, New Orleans Academy of Ophthalmology. Kugler Publications, New York, 1993, pp. 191 – 192
- ▶ Melia BM, Diener-West M. Modeling interrater agreement on an ordered categorical scale. In: Lange N, Ryan L (eds): Case Studies in Biometry, John Wiley and Sons, New York, 1994, pp. 323 – 338
 - ▶ Davis MD, Fine SL, Kupfer C. The collaborative Ocular Melanoma Study. Arch Ophthalmol 1994; 112: 730 – 731
 - ▶ Schachat AP. Management of uveal melanoma: a continuing dilemma. Collaborative Ocular Melanoma Study Group. Cancer 1994; 74: 3073 – 3075
 - ▶ Kelly MP, Hahn KM. The Collaborative Ocular Melanoma Study. J Ophthal Photography 1995; 17: 18 – 21
 - ▶ Fine SL. No one knows the preferred management for choroidal melanoma. Am J Ophthalmol 1996; 122: 106 – 108
 - ▶ Goldsborough IL, Church RY, Newhouse MM, Hawkins BS. How clinic coordinators spend their time in a multicenter clinical trials. Applied Clin Trials 1998; 7: 33 – 40
 - ▶ Servodidio C, Abramson D. Collaborative Ocular Melanoma Study. (Chapter 15) In: Kertes PJ, Conway MD (eds): Clinical Trials in Ophthalmology: A Summary and Practice Guide. Williams & Wilkins, Baltimore, 1998; pp.257 – 270
 - ▶ Fine SL. Collaborative ocular melanoma study group. Arch Fam Med 1999; 8: 11 – 12
 - ▶ Soparker CN, O'Brien JM, Albert DM. Investigation of the role of the ras protooncogene point mutation in human uveal melanomas. Invest Ophthalmol Vis Sci 1993; 34: 2203 – 2209
 - ▶ Hawkins BS, McBride R, Singer SW. (eds): Data Management for Multicenter Studies: Methods and Guidelines. Controlled Clin Trials 16(2, suppl): 1 – 179, 1995. [This monograph includes several examples from COMS data management systems to illustrate current standards in multicenter clinical trials.]
 - ▶ Umlas J, Diener-West M, Robinson NL et al. Comparison of transillumination and histologic slide measurements of choroidal melanoma. Arch Ophthalmol 1997; 115: 474 – 477
 - ▶ Diener-West M, Connor PB, Newhouse MM, Hawkins BS. Feasibility of keying data from screen-displayed facsimile images in an ongoing trial: the collaborative ocular melanoma study. Control Clin Trials 1998; 19: 39 – 49
 - ▶ Ruiz RS, El-Harazi S, Albert DM, Bryar PJ. Cardiac metastasis of choroidal melanoma. Arch Ophthalmol 1999; 117: 1558 – 1559
 - ▶ Knutsen S, Hafslund R, Monge OR et al. Dosimetric verification of a dedicated 3D treatment planning system for episcleral plaque therapy. Int J Radiat Oncol Biol Phys 2001; 51: 1159 – 1166
 - ▶ Grostern RJ, Slusker Shternfeld I, Bacus SS et al. Absence of type I estrogen receptors in choroidal melanoma: analysis of Collaborative Ocular Melanoma Study (COMS) eyes. Am J Ophthalmol 2001; 131: 788 – 791
 - ▶ Tabandeh H, Chaudhry NA, Murray TG et al. Intraoperative echographic localization of iodine-125 episcleral plaque for brachytherapy of choroidal melanoma. Am J Ophthalmol 2000; 129: 199 – 204
 - ▶ Albert DM. The ocular melanoma story. LIII Edward Jackson Memorial Lecture: Part II. Am J Ophthalmol 1997; 123: 729 – 741
 - ▶ Freire JE, De Potter P, Brady LW, Longton WA. Brachytherapy in primary ocular tumors. Semin Surg Oncol 1997; 13: 167 – 176
 - ▶ Reader S, Grigg J, Billson FA. Choroidal melanoma: a review of the experience of the Sydney Eye Hospital Professorial Unit 1979 – 1995. Aust N Z J Ophthalmol 1997; 25: 15 – 24
 - ▶ Char DH, Kroll S, Quivey JM, Castro J. Long term visual outcome of radiated uveal melanomas in eyes eligible for randomisation to enucleation versus brachytherapy. Br J Ophthalmol 1996; 80: 117 – 124
 - ▶ Sanders DG, Mooy CM. Ocular findings in cerebro-ocular-myopathy syndrome (COMS). A possible role of growth factors? Int Ophthalmol 1993; 17: 223 – 228
 - ▶ Shields JA, Shields CL. Current management of posterior uveal melanoma. Mayo Clin Proc 1993; 68: 1196 – 1200

COMS-Related Publications

Recommended Reading

- ▶ Jones R, Gore E, Mieler W et al. Posttreatment visual acuity in patients treated with episcleral plaque therapy for choroidal melanomas: dose and dose rate effects. Int J Radiat Oncol Biol Phys 2002; 52: 989 – 995
- ▶ Sieving PA. Fifteen years of work: the COMS outcomes for medium-sized choroidal melanoma. Arch Ophthalmol 2001; 119: 1067 – 1068
- ▶ Earle JD. Results from the Collaborative Ocular Melanoma Study (COMS) of enucleation versus preoperative radiation therapy in the management of large ocular melanomas. Int J Radiat Oncol Biol Phys 1999; 43: 1168 – 1169

Additional Background Reading

- ▶ Marcus DM, Minkovitz JB, Wardwell SD, Albert DM. The value of nucleolar organizer regions in uveal melanoma. The Collaborative Ocular Melanoma Study Group. Am J Ophthalmol 1990; 110: 527 – 534
- ▶ Markowitz JA, Hawkins BS, Diener-West M, Schachat AP. A review of mortality from choroidal melanoma. I. Quality of published reports, 1966 through 1988. Arch Ophthalmol 1992; 110: 239 – 244
- ▶ Diener-West M, Hawkins BS, Markowitz JA, Schachat AP. A review of mortality from choroidal melanoma. II. A meta-analysis of 5-year mortality rates following enucleation, 1966 through 1988. Arch Ophthalmol 1992; 110: 245 – 250
- ▶ Taylor KM. Integrating conflicting professional roles: physician participation in randomized clinical trials. Soc Sci Med 1992; 35: 217 – 224
- ▶ Taylor KM. Physician participation in a randomized clinical trial for ocular melanoma. Ann Ophthalmol 1992; 24: 337 – 344
- ▶ Albert DM, Niffenegger AS, Willson JK. Treatment of metastatic uveal melanoma: review and recommendations. Surv Ophthalmol 1992; 36: 429 – 438

Additional Suggested Literature: Review Articles

Didactic review articles are an excellent source of information and perspective for ophthalmologists-in-training. Some examples of useful reviews are listed below; the list is by no means comprehensive. Residents should be encouraged to search the literature on a regular basis to stay aware of new reviews and original clinical studies.

- ▶ Lama PJ, Fechtner RD. Antifibrotics and wound healing in glaucoma surgery. Surv Ophthalmol 2003; 48: 314 – 346
- ▶ Racette L, Wilson MR, Zangwill LM, Weinreb RN, Sample PA. Primary open-angle glaucoma in blacks: a review. Surv Ophthalmol 2003; 48: 295 – 313

- ▶ Dollfus H, Porto F, Caussade P et al. Ocular manifestations in the inherited DNA repair disorders. *Surv Ophthalmol* 2003; 48: 107–122
- ▶ Menon GJ, Rahman I, Menon SJ, Dutton GN. Complex visual hallucinations in the visually impaired: the Charles Bonnet Syndrome. *Surv Ophthalmol* 2003; 48: 58–72
- ▶ Shields JA, Shields CL. Rhabdomyosarcoma: review for the ophthalmologist. *Surv Ophthalmol* 2003; 48: 39–57
- ▶ Chan JW. Paraneoplastic retinopathies and optic neuropathies. *Surv Ophthalmol* 2003; 48: 12–38
- ▶ Turbeville SD, Cowan LD, Gass JD. Acute macular neuroretinopathy: a review of the literature. *Surv Ophthalmol* 2003; 48: 1–11
- ▶ Special supplement on diabetic retinopathy. *Surv Ophthalmol* 2002; 47: 547–561
- ▶ Miki A, Haselgrove JC, Liu GT. Functional magnetic resonance imaging and its clinical utility in patients with visual disturbances. *Surv Ophthalmol* 2002; 47: 562–579
- ▶ Fingert JH, Stone EM, Sheffield VC, Alward WL. Myocilin glaucoma. *Surv Ophthalmol* 2002; 47: 547–561
- ▶ Fan-Paul NI, Li J, Miller JS, Florakis GJ. Night vision disturbances after corneal refractive surgery. *Surv Ophthalmol* 2002; 47: 533–546
- ▶ Auw-Haendrich C, Staubach F, Witschel H. Optic disk drusen. *Surv Ophthalmol* 2002; 47: 515–532
- ▶ Coupland SE, Hummel M, Stein H. Ocular adnexal lymphomas: five case presentations and a review of the literature. *Surv Ophthalmol* 2002; 47: 470–490
- ▶ Bouzas EA, Karadimas P, Pournaras CJ. Central serous chorioretinopathy and glucocorticoids. *Surv Ophthalmol* 2002; 47: 431–448
- ▶ Robertson DM. Non-cancerous ophthalmic clues to non-ocular cancer. *Surv Ophthalmol* 2002; 47: 397–430
- ▶ Margo CE, Harman LE, Mulla ZD. The reliability of clinical methods in ophthalmology. *Surv Ophthalmol* 2002; 47: 375–386
- ▶ Walton W, Von Hagen S, Grigorian R, Zarbin M. Management of traumatic hyphema. *Surv Ophthalmol* 2002; 47: 297–334
- ▶ Durrani OM, Gordon C, Murray PI. Primary anti-phospholipid antibody syndrome (APS): current concepts. *Surv Ophthalmol* 2002; 47: 215–238
- ▶ Lee AG, Hayman LA, Brazis PW. The evaluation of isolated third nerve palsy revisited: an update on the evolving role of magnetic resonance, computed tomography, and catheter angiography. *Surv Ophthalmol* 2002; 47: 137–157
- ▶ Read RW, Zamir E, Rao NA. Neoplastic masquerade syndromes. *Surv Ophthalmol* 2002; 47: 81–124
- ▶ Lueder GT. Anomalous orbital structures resulting in unusual strabismus. *Surv Ophthalmol* 2002; 47: 27–35
- ▶ Boyd SR, Young S, Lightman S. Immunopathology of the non-infectious posterior and intermediate uveitides. *Surv Ophthalmol* 2001; 46: 209–233
- ▶ Ramsay A, Lightman S. Hypopyon uveitis. *Surv Ophthalmol* 2001; 46: 1–18
- ▶ Girkin CA, Miller NR. Central disorders of vision in humans. *Surv Ophthalmol* 2001; 45: 379–405
- ▶ Lee AG, Hayman LA, Ross AW. Neuroimaging contrast agents in ophthalmology. *Surv Ophthalmol* 2000; 45: 237–253
- ▶ Onwochei BC, Simon JW, Bateman JB, Couture KC, Mir E. Ocular colobomata. *Surv Ophthalmol* 2000; 45: 175–194
- ▶ Wolintz RJ, Trobe JD, Cornblath WT et al. Common errors in the use of magnetic resonance imaging for neuro-ophthalmic diagnosis. *Surv Ophthalmol* 2000; 45: 107–114
- ▶ Scholl HP, Zrenner E. Electrophysiology in the investigation of acquired retinal disorders. *Surv Ophthalmol* 2000; 45: 29–47
- ▶ Cassidy L, Taylor D, Harris C. Abnormal supranuclear eye movements in the child: a practical guide to examination and interpretation. *Surv Ophthalmol* 2000; 44: 479–506
- ▶ Ettl A, Zwrtek K, Daxer A, Salomonowitz E. Anatomy of the orbital apex and cavernous sinus on high-resolution magnetic resonance images. *Surv Ophthalmol* 2000; 44: 303–323
- ▶ Wright JD Jr., Boger WP 3rd. Visual complaints from healthy children. *Surv Ophthalmol* 1999; 44: 113–121
- ▶ Lacey B, Chang W, Rootman J. Nonthyroid causes of extraocular muscle disease. *Surv Ophthalmol* 1999; 44: 187–213
- ▶ Abdelsalam A, Del Priore L, Zarbin MA. Drusen in age-related macular degeneration: pathogenesis, natural course, and laser photocoagulation-induced regression. *Surv Ophthalmol* 1999; 44: 1–29
- ▶ Owsley C, McGwin G Jr. Vision impairment and driving. *Surv Ophthalmol* 1999; 43: 535–550
- ▶ Chu TG, Green RL. Suprachoroidal hemorrhage. *Surv Ophthalmol* 1999; 43: 471–486
- ▶ Messmer EM, Foster CS. Vasculitic peripheral ulcerative keratitis. *Surv Ophthalmol* 1999; 43: 379–396
- ▶ Jonas JB, Budde WM, Panda-Jonas S. Ophthalmoscopic evaluation of the optic nerve head. *Surv Ophthalmol* 1999; 43: 293–320
- ▶ Kresloff MS, Castellarin AA, Zarbin MA. Endophthalmitis. *Surv Ophthalmol* 1998; 43: 193–224
- ▶ Moorthy RS, Valluri S, Jampol LM. Drug-induced uveitis. *Surv Ophthalmol* 1998; 42: 557–570
- ▶ Carlson AN, Stewart WC, Tso PC. Intraocular lens complications requiring removal or exchange. *Surv Ophthalmol* 1998; 42: 417–440
- ▶ Ho AC, Guyer DR, Fine SL. Macular hole. *Surv Ophthalmol* 1998; 42: 393–416
- ▶ Seregard S. Conjunctival melanoma. *Surv Ophthalmol* 1998; 42: 321–350
- ▶ Wagoner MD. Chemical injuries of the eye: current concepts in pathophysiology and therapy. *Surv Ophthalmol* 1997; 41: 275–313
- ▶ Jonas JB, Dichtl A. Evaluation of the retinal nerve fiber layer. *Surv Ophthalmol* 1996; 40: 369–378
- ▶ De La Paz MA, Boniuk M. Fundus manifestations of orbital disease and treatment of orbital disease. *Surv Ophthalmol* 1995; 40: 3–21
- ▶ Bird AC, Bressler NM, Bressler SB et al. An international classification and grading system for age-related maculopathy and age-related macular degeneration. The International ARM Epidemiological Study Group. *Surv Ophthalmol* 1995; 39: 367–374
- ▶ Weinberg DA, Lesser RL, Vollmer TL. Ocular myasthenia: a protean disorder. *Surv Ophthalmol* 1994; 39: 169–210
- ▶ Brodsky MC. Congenital optic disk anomalies. *Surv Ophthalmol* 1994; 39: 89–112
- ▶ Steinsapir KD, Goldberg RA. Traumatic optic neuropathy. *Surv Ophthalmol* 1994; 38: 487–518
- ▶ Journee-de Korver JG, Keunen JE. Thermotherapy in the management of choroidal melanoma. *Prog Retin Eye Res* 2002; 21: 303–317