


INTERNATIONAL COUNCIL OF OPHTHALMOLOGY

HANDBOOK FOR MEDICAL STUDENTS LEARNING OPHTHALMOLOGY



**Compiled by The Task Force on Undergraduate Teaching in Ophthalmology of
the International Council of Ophthalmology and based on their curriculum 2009**

Dear Medical Student

Welcome to Ophthalmology! In this booklet we have put together tables of core knowledge that we think you need to know and key ophthalmic disorders we think you need to have seen. There are descriptions and colour pictures of the different causes of The Red Eye and the common causes of acute loss of vision. This pocket sized book summaries the key points in the ophthalmology curriculum compiled by the Task Force of the International Council of Ophthalmology and is a format that is very portable!

We hope you find this useful. Ophthalmology is a fascinating discipline and you can see the pathology directly. We hope that we can stimulate your interest to read further and to further develop your skills.

Good Luck!!



Sue Lightman and Peter McCluskey

on behalf of the International Council of Ophthalmology 2009

Have you seen?	Tick if yes	Do you know how it is caused and treated?	Tick if yes	Note for you: Remember to look it up
Red eye				
Stye				
chalazion				
Acute uveitis				
Herpes simplex keratitis				
Conjunctivitis: bacterial, viral, allergic, neonatal				
Infective keratitis				
Blepharitis				
Dry eye				
Pterygium				
Subconjunctival haemorrhage				
Corneal abrasion				
Ocular trauma and when to consider ocular penetration				
Cataract				
Cataract surgery with intraocular lens insertion				
Pupils -Afferent pupillary defect				
Dilated pupil				

Horner's or Adie's pupils				
Cranial nerve palsies				
Facial nerve palsy and ocular exposure				
3 rd nerve palsy				
6 th nerve palsy				
Optic disc				
Normal				
Pale				
Cupped				
Papilloedema				
Retina				
Normal				
Vein occlusion – central and branch				
Artery occlusion/embolus				
Diabetic retinopathy				
Hypertensive retinopathy				
Age related macular disease				
Squint				
Eso-deviation				
Exo -deviation				
Orthoptic assessment				
Refractive errors				

Manual refraction				
Automated refraction				
Types of lenses used				
Presbyopia				
Other eye problems				
Thyroid eye disease				
Nystagmus				
Leucocoria				

Have you done	Tick if yes	Points to check
External examination of a normal eye		
Used a Snellen chart		
Written visual acuity correctly		
Tested colour vision with Ishihara charts		
Tested pupillary reflexes with a light		
Tested eye movements		
Tested visual fields to confrontation		
Dilated a pupil		
Used a direct ophthalmoscope with each hand		
Seen a red reflex		
Seen the optic disc		
Seen the retina and the blood vessels		

ACUTE RED EYE

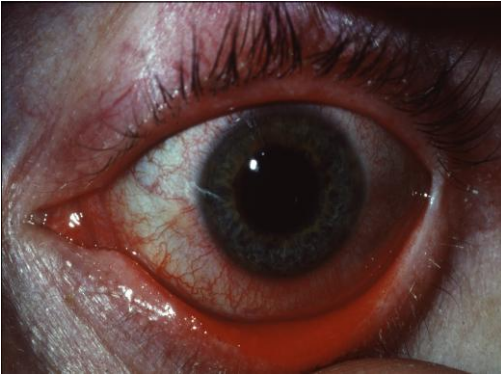There are many conditions that can lead to a red eye, serious and not serious. May be painful or painless and detailed examination required to sort them out.

Painless

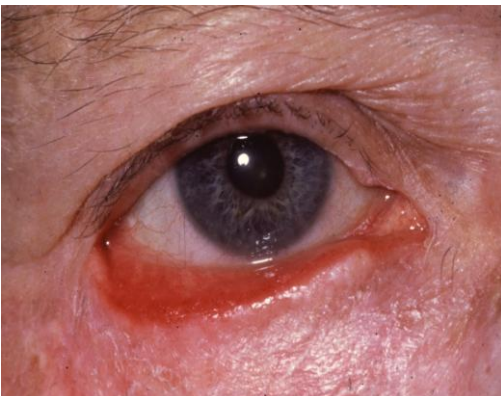
It is rare for a painless red eye to require an urgent (same day) ophthalmological assessment.

Diffuse conjunctival redness

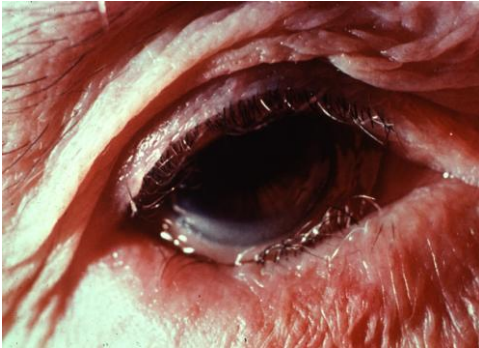Blepharitis: Very common non specific generalised inflammation of the eyelids. Treat with daily lid hygiene, low dose tetracyclines/doxycycline, lubrication as required with routine referral.



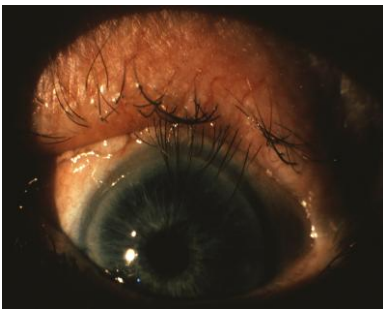Ectropion: Lid turning outwards with exposure of conjunctival sac-. Eye may be sore and watery. Routine referral and may require surgery



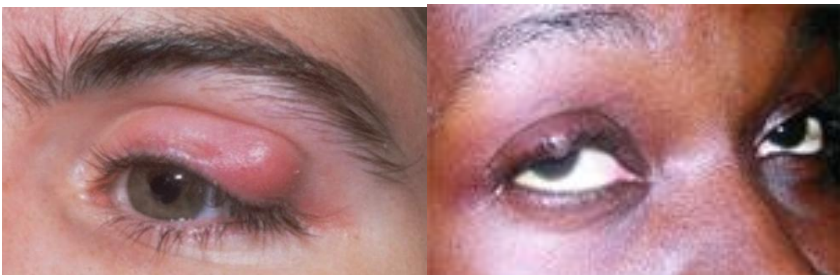Entropion lids turning inwards and eyelashes may abrade cornea –check condition of cornea with fluorescein. If corneal staining , tape back eyelid away from the cornea and refer urgent (same day)ly..



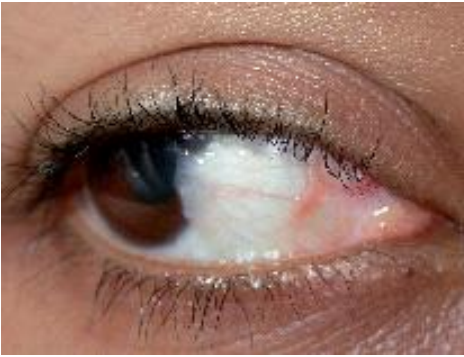Trichiasis- ingrowing eyelashes epilate when touching cornea, lubricate with routine referral.



Eyelid lesion (chalazion or sty) provided there is no overt eyelid infection /inflammation and no ocular involvement, routine referral. Consider topical antibiotics.



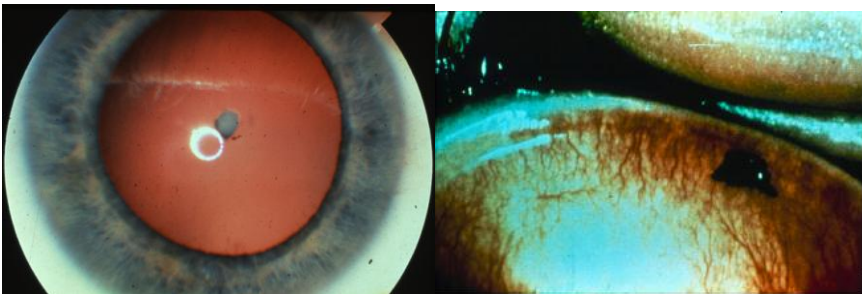
Pterygium



A raised white/yellowish fleshy lesion at the limbus that may become painful and red if inflamed. Treatment: lubrication and sunglasses. Routine ophthalmological referral for further management.

Corneal foreign body and ocular trauma

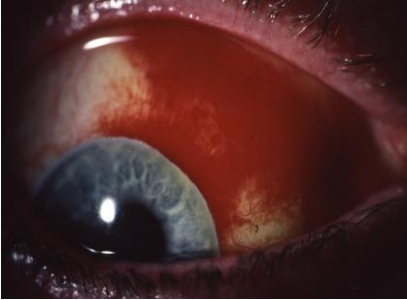
Remove foreign body, treat with topical antibiotics. Check for more severe ocular trauma such as penetration of the eye, treat with topical antibiotics if trauma area is small Refer if unsure



Beware signs of perforation of the eye – eye soft, iris protruding, irregular pupil

Subconjunctival haemorrhage:

Blood under the conjunctiva – usually unilateral, localised and sharply circumscribed. Underlying sclera not visible.

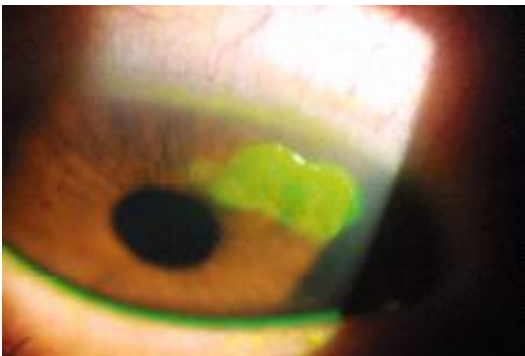


No inflammation, pain or discharge. Vision unchanged. Possible association with minor injuries including rubbing. Common with use of anti-platelet agents and anticoagulants.

Management: reassure. Check BP, blood coagulation studies or INR if indicated. Routine referral only if condition worsens or pain develops.

Painful – most cases of conjunctivitis are painful but there are other causes as well.

Corneal erosion

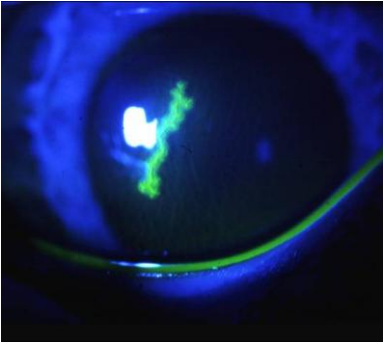


Symptoms: something went into the eye, very sore, watering++

Signs: eye red and watery, area where corneal epithelium not intact stains with fluorescein

Management: check no foreign body, topical antibiotics and pad eye. See if pain or vision worse

Herpes simplex keratitis:

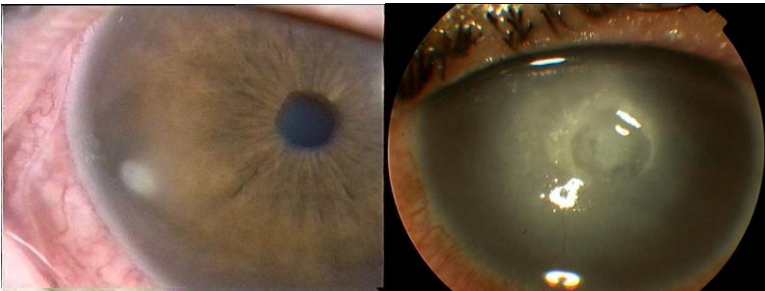


Symptoms: sore red eye , not sticky

Signs: abnormal corneal epithelium in dendrite pattern which stain with fluorescein

Management: Topical aciclovir and see ophthalmologist the following day

Bacterial corneal infection

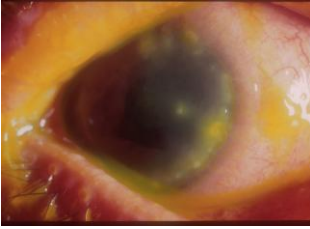


Symptoms: eye sore and red , often in contact lens wearer, vision may be affected

Signs: white area on cornea, maybe peripheral or central

Management: urgent (same day) referral to ophthalmologist

Marginal keratitis

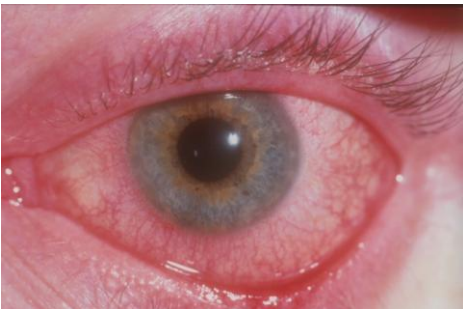


Symptoms: sore red eye, may be sticky, may or may not have blurry vision

Signs: white areas on periphery of cornea which may be thinner than normal usually associated with blepharitis

Management: refer to ophthalmologist same day

Viral conjunctivitis



Contact history with recent eye or upper respiratory tract infection symptoms (especially children). Highly contagious

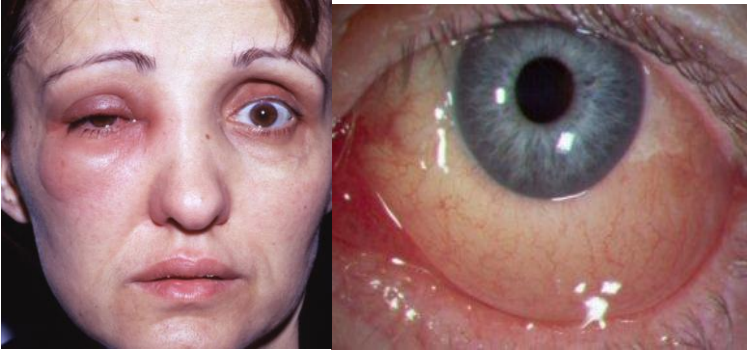
Symptoms: Burning sensation and watery discharge (different from purulent exudate in bacterial infections). Classically begins in one eye with rapid spread to the other, often pre-auricular lymphadenopathy

Signs: eye red and watery. Swollen conjunctiva particularly in lids

Management: Will resolve on own and treatment aimed at comfort. Cool compresses, regular lubricants (without preservative). Antibiotic drops if indicated. Never steroids!

Resolution may take weeks. Refer if photophobia and decrease in visual acuity, severe disease lasting longer than 3 weeks.

Allergic conjunctivitis

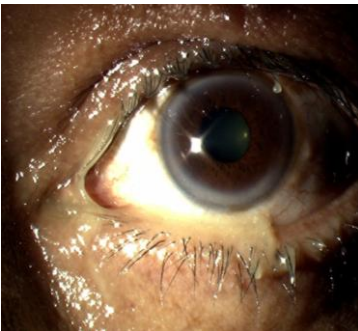

Symptoms: eyes itch++ and are red and sore

Signs: swelling and signs of atopy eg asthma, eczema

Management: Remove allergens where possible, topical anti-histamines, cool compresses, refer if not better in 3 days

Bacterial conjunctivitis:

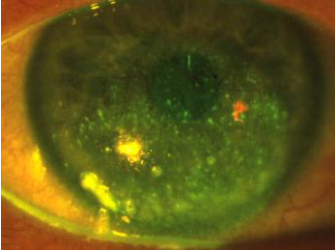


Symptoms: eye red and sticky, often bilateral

Signs: red eyes with purulent discharge No corneal or anterior chamber Involvement. Systemically well.

Management: regular hygiene to minimise secretion buildup, topical antibiotics for 5 days. Refer if vision is affected., if does not improve with treatment after 2 days or worsens and if after treatment for 5 days.

Dry Eyes:



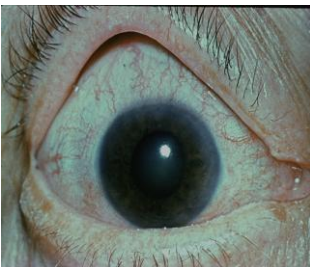
Common chronic ocular condition that is often caused by or coexists with other ocular diseases.

Symptoms: soreness, grittiness often worsen in the evening.

Signs: depends on degree of dryness. If not severe, eye injected with poor tear film. Fluorescein staining of corneal epithelium

Management: Usually good relief with lubricants – put in as often as necessary to relieve symptoms– use preservative free drops if > x4 per day and ointment on eyeball before sleep. Routine referral if symptoms not improved.

Acute angle closure glaucoma



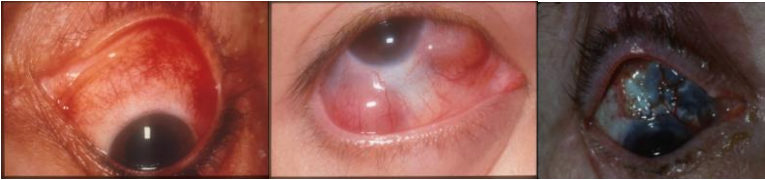Symptoms: Painful eye with systemic symptoms including headache, nausea and vomiting

Signs: More common in Asian races, eye red, very tender and feels hard on palpation, cornea usually has hazy appearance, Anterior chamber is shallow with irregular semidilated pupil.

.Management: Urgent (same day) referral to ophthalmologist.

Ciliary injection/scleral involvement

Scleritis



Diffuse

Nodular

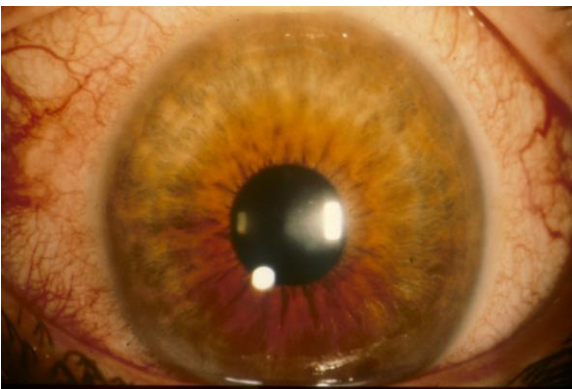
Necrotising

Symptoms: eye pain which radiates to head and wakes them at night

Signs: Eye is red, may have nodules and necrotic patch, sclera may be discolored and is tender to palpation. Associated history of rheumatoid arthritis, vascular or connective tissue disease

Management: Urgent (same day) referral to ophthalmologist

Acute Anterior Uveitis (Iritis)

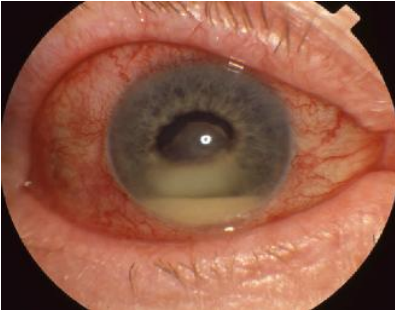


Symptoms: photophobia, eye red and sore, vision may or may not be affected

Signs: red eye with ciliary injection around iris, anterior chamber appears cloudy from cells and flare.

Management: urgent (same day) referral to ophthalmologist

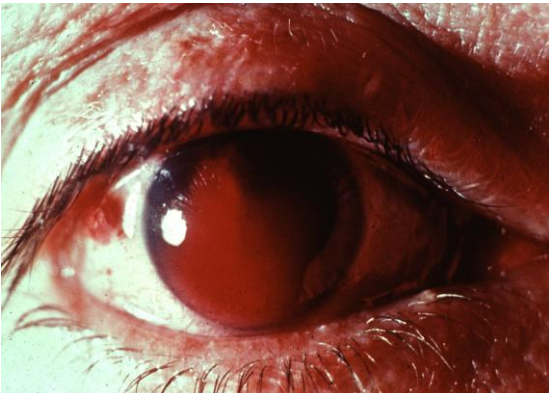
Hypopyon



Visible accumulation of white cells inferiorly seen in severe uveitis.

Urgent (same day) referral for investigation of infection, inflammation or ocular Malignancy

Hyphaema



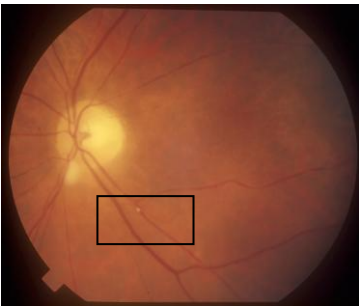Symptoms: eye is red and severe loss of vision following trauma - consider non-accidental injury in children and blood dyscrasias.

Signs: eye has visible blood inside and cornea may also be stained. Eye may be very sore if intraocular pressure is raised

Management: Bed rest, eye pad. Urgent (same day) assessment by ophthalmologist.

Acute visual disturbance/Sudden loss of vision

Transient Ischaemic Attack (Amaurosis Fugax)

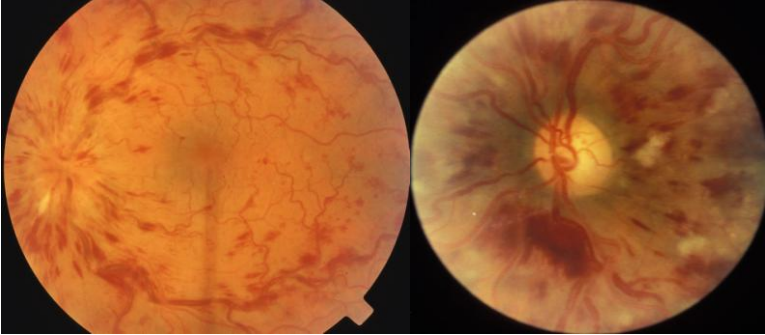


Symptoms: Monocular visual loss that usually lasts seconds to minutes, but may last 1-2 hours. Vision returns to normal.

Signs : Essentially normal fundus exam (an embolus within a retinal arteriole is only occasionally seen. Other neurological signs associated with ischemia of cerebral hemispheres.

Investigation and management: Assessment of cardiovascular risk factors, blood count /electrolytes /lipids/fasting blood sugar, thrombophilia screen. Echocardiogram. Carotid doppler studies. Start aspirin, referral to neurology/cardiology or vascular surgery as appropriate. Patients with recurrent episodes of amaurosis fugax require immediate diagnostic and therapeutic intervention.

Central Retinal Vein Occlusion

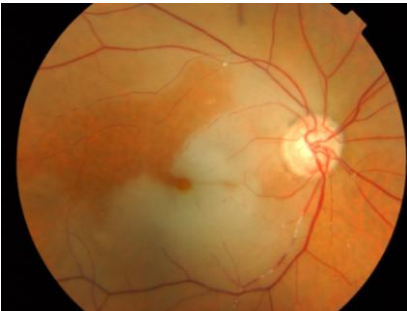


Symptoms : Sudden and painless loss of vision.

Signs: dilated tortuous veins, cotton wool spots, optic disc swelling, retinal haemorrhage visible in all four quadrants which may obscure much of fundus detail.
Predisposing factors : increasing age, hypertension, diabetes.

Investigation and Management : Screen for diabetes and hypertension, exclude glaucoma. Routine referral for an ophthalmological opinion.

Central Retinal Artery Occlusion



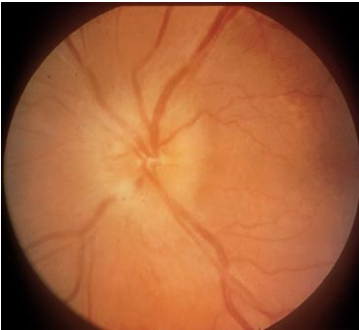Symptoms : Sudden and painless loss of vision.

Signs: Visual acuity $< 6/60$, Relative Afferent Pupillary Defect (RAPD)
Fundus examination: pale retina (abnormal and asymmetrical red reflex)
cherry red spot-area of cilioretinal sparing

Investigation and Management: Urgent (same day) ESR and CRP to exclude Giant

Cell Arteritis., urgent (same day) referral to ophthalmologist to see whether any immediate treatment is possible. TIA workup

Optic neuritis

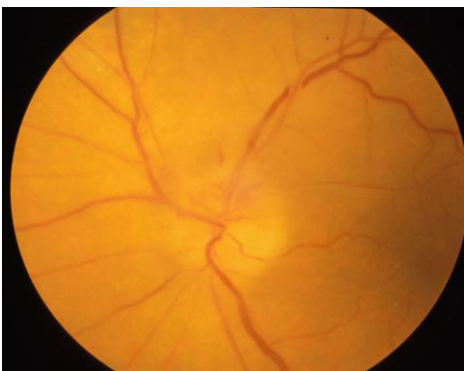

Symptoms: Painless loss of vision over hours to days. Vision loss can be subtle or profound. Orbital pain usually associated with eye movement.

Signs: Usually females aged 18-45, may have other focal neurological signs, reduced visual acuity and colour vision. Relative Afferent Pupillary Defect (RAPD), central scotoma, optic disc may look normal (retrobulbar neuritis) or be swollen.

Investigation and Management: Complete ophthalmic and neurological examination. Blood count/Erythrocyte Sedimentation Rate (ESR), urgent (same day) referral to ophthalmologist may be indicated for further MRI investigation and intravenous steroid treatment may be required. There are NO indications for oral corticosteroids as initial treatment.

Ischaemic Optic Neuropathy (AION)/Giant Cell Arteritis



Transient visual loss may precede an ischaemic optic neuropathy or central retinal artery occlusion.

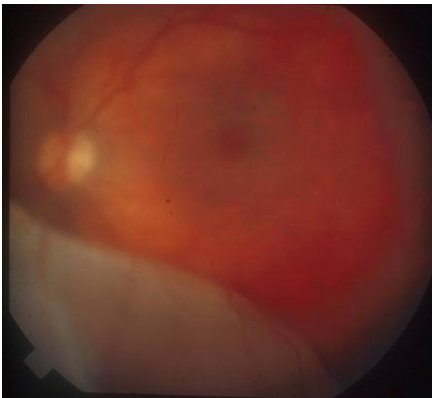Symptoms: Temporal headache., scalp tenderness, jaw claudication, fever and night sweats, generalised muscle pain and weakness.

Signs: Typically affects patients greater than 50 years. May include the following: Afferent pupillary defect, poor visual acuity, often count fingers only, palpable and tender non-pulsatile temporal artery, swollen pale optic disc.

Investigation and Management: Immediate ESR/CRP (NB classically but not always raised in GCA), referral to ophthalmologist for urgent (same day) (same day) steroid treatment and temporal artery biopsy.

Retinal Detachment

Occurs when there is separation of sensory retina from the retinal pigment epithelium. Most common aetiology is a predisposing retinal hole tear – often associated with myopia but may follow trauma



Symptoms : painless loss of vision. The patient may have encountered a recent history of increased number of visual floaters and/ or visual flashes. There may be a “dark shadow” in the vision of the affected eye.

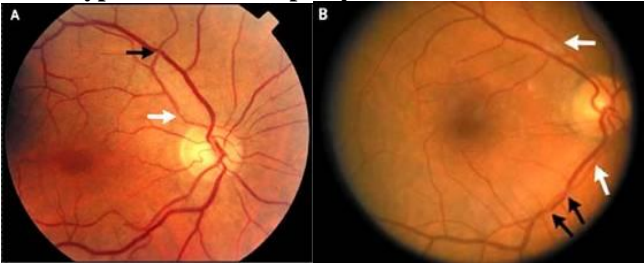
Signs:, grey area of retina which is where it is detached, vision reduced if retina detaches and involves the macula.

Management: urgent (same day) referral to ophthalmologist

The eye in systemic hypertension

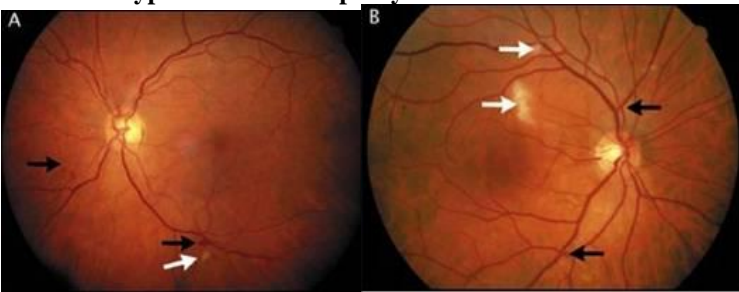
(reproduced with permission Wong TY, Mitchell P. Hypertensive retinopathy. NEJM 2004 Nov 25;351(22):2310-7)

Mild hypertensive retinopathy



Generalised arteriolar narrowing, focal arteriolar narrowing, a-v nicking, opacity of arteriolar wall (copper wiring) **systemic associations:** OR 1-2 stroke, coronary heart disease and death

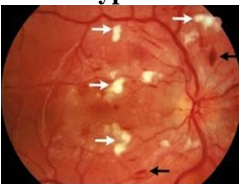Moderate hypertensive retinopathy



Any type of haemorrhage, microaneurysm, CWS, exudates or combination

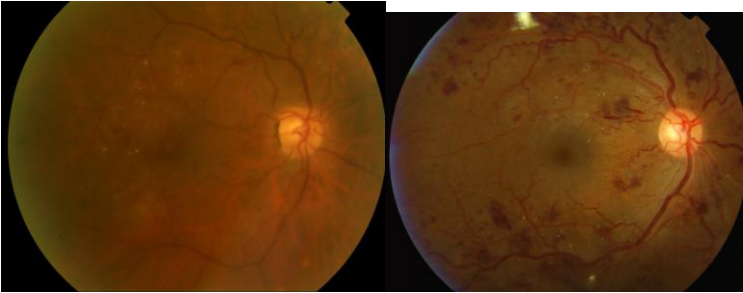
Systemic association: OR >2 stroke, cognitive decline, death from cardiovascular causes

Severe hypertensive retinopathy

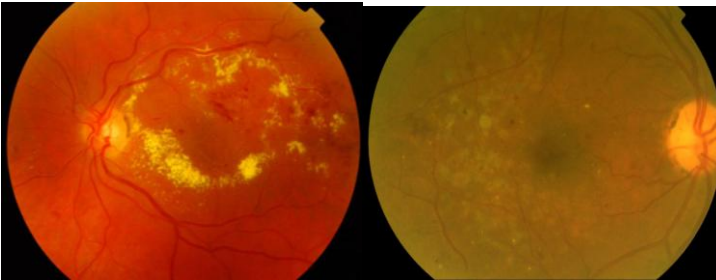


Signs of moderate retinopathy plus optic disc swelling. Strong association with death

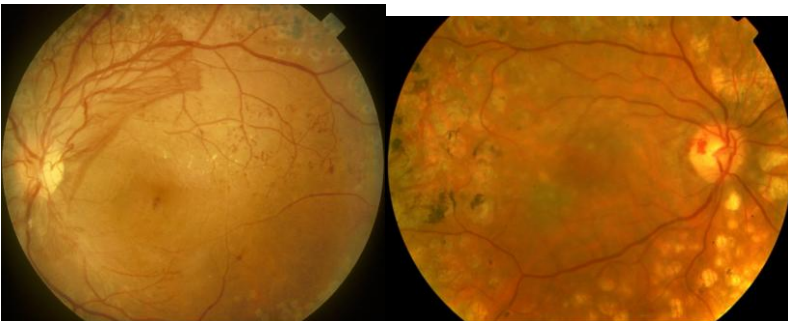
The eye in diabetes



Classic features of background retinopathy with a few exudates (left picture) and more severe (right picture) with haemorrhages, venous beading and cotton wool spot



Severe diabetic maculopathy with exudates and clinically significant macular oedema (left picture) and another eye after macular laser (right picture) showing laser burns



Severe proliferative retinopathy (left picture) with new vessels arising from optic disc and right picture shows lots of laser burns used to destroy the peripheral ischaemic retina and cause the new vessels to regress